

Hairy cell leukaemia: ESMO Clinical Practice Guidelines for diagnosis, treatment and follow-up[†]

T. Robak¹, E. Matutes², D. Catovsky³, P. L. Zinzani⁴ & C. Buske⁵, on behalf of the ESMO Guidelines Committee*

¹Department of Hematology, Medical University of Lodz, Lodz, Poland; ²Haematopathology Unit, Hospital Clinic, Barcelona University, Barcelona, Spain;

³Haemato-Oncology Research Unit, The Institute of Cancer Research, Sutton, Surrey, UK; ⁴Seragnoli Institute of Hematology, University of Bologna, Bologna, Italy;

⁵Comprehensive Cancer Center Ulm, Institute of Experimental Cancer Research, University Hospital, Ulm, Germany

Incidence and epidemiology

Classical hairy cell leukaemia (HCL) is a B-cell chronic lymphoproliferative disorder characterised by splenomegaly, pancytopenia and bone marrow involvement with fibrosis. HCL represents 2% of adult leukaemia. Approximately 1600 new cases per year are diagnosed in Europe [1], with a median age of 52 years at the time of diagnosis. The disease occurs more often in men than in women, with a ratio of approximately 4:1 [2]. In the USA, a higher frequency of HCL is observed among white Americans than among African-Americans or Asians, as well as in patients following exposure to the herbicide 'Agent Orange', used during the Vietnam War [3]. HCL variant (HCL-V) is classified among the unclassifiable splenic B-cell leukaemia/lymphoma that is no longer biologically related to classical HCL. It is included in the World Health Organization (WHO) classification as a provisional entity [4]. HCL-V is an uncommon disorder, accounting for approximately 0.4% of chronic lymphoid malignancies and 10% of all HCL cases, without sexual predominance. The median age of the patients is 71 years.

diagnosis and pathology/molecular biology

The examination of peripheral blood films and immunophenotyping allows for a diagnosis to be established in most cases (Table 1) [I, C] [5, 6]. The neoplastic cells are twice the size of a lymphocyte and have a round or kidney-shaped nucleus with loose chromatin and abundant pale cytoplasm with projections. Monocytopenia and macrocytosis are very common; other cytopenias may be present. A diagnosis of HCL based on cytology can be effectively confirmed by flow cytometry studies using anti-B-cell monoclonal antibodies such as CD19, CD20 or CD22, together with a panel of antibodies such as CD11c, CD25, CD103 and CD123, which are more specific to HCL; this

combination will allow for the differentiation of HCL from other B-cell leukaemias and lymphomas with circulating villous cells [5, 6]. In addition, strong expression of CD200 is characteristic of HCL and may be useful for the diagnosis in difficult cases [7].

HCL-V typically presents with high lymphocyte counts, with the cells being nucleolated and lacking monocytopenia. Flow cytometry will indicate the cells to be CD11c+ and often CD103+ but very rarely CD25+ and CD123+. There is an overlap with splenic diffuse red pulp lymphoma, and distinguishing between these two diseases may be difficult. A bone marrow examination is required for the diagnosis, particularly after treatment, to assess response [I, C].

As the bone marrow can rarely be aspirated ('dry-tap') in classical HCL, diagnosis is typically performed by a bone marrow trephine biopsy. The degree and pattern of infiltration varies from mild interstitial to diffuse, and the lymphoid cells are surrounded by a clear halo due to the abundant cytoplasm, giving the characteristic 'fried egg' pattern. In HCL-V, the infiltration is either intrasinusoidal or interstitial.

Immunohistochemistry with the monoclonal antibodies CD20, CD72 (DBA44), CD11c, CD25, CD103, annexin A1 and tartrate-resistant acid phosphatase stain will highlight the lymphoid infiltrates and support the diagnosis of classical HCL [6]. However, annexin A1 is not suitable for detecting residual disease after treatment as it stains myeloid cells also. Cyclin D1 may be weakly positive but differential diagnosis with mantle cell lymphoma rarely arises. Recently, monoclonal antibodies that detect the mutated BRAF protein have been developed and shown to be useful for the diagnosis and detection of minimal residual disease (MRD) [8]. Although this requires validation, preliminary data suggest that this marker has high specificity and sensitivity for HCL [II, C].

The main distinguishing features between HCL and HCL-V are outlined in Table 2. HCL does not have a distinct chromosomal abnormality. The majority of the cases have mutations of the immunoglobulin heavy chain (*IGHV*) gene, suggesting that the disease arises on a memory B cell. Unlike other splenomegalic disorders such as splenic marginal zone lymphoma or HCL-V, there is no evidence of specific *IGHV*, *IGHD*, *IGHJ*

*Correspondence to: ESMO Guidelines Committee, ESMO Head Office, via L. Taddei 4, CH-6962 Viganello-Lugano, Switzerland.
E-mail: clinicalguidelines@esmo.org

[†]Approved by the ESMO Guidelines Committee, July 2015.

Table 1. Diagnostic work-up of classical HCL

Peripheral blood film morphology [I, C]
 Flow cytometry in peripheral blood and bone marrow aspirate [I, C]
 Bone marrow trephine biopsy with immunohistochemistry [I, C]
BRAF mutation of exon 15 in difficult cases [II, C]

HCL, hairy cell leukaemia.

Table 2. Diagnostic criteria for HCL and HCL-V

Characteristics	Classical HCL	HCL-V
Bone marrow aspiration	Difficult (often dry tap)	Easy
Lymphocytosis	–	+
Monocytopenia	+	–
Prominent nucleoli	–	+
Cytoplasmic projections	+	+
CD25	+	–
FMC7, CD20, CD22, CD11c	+	+
CD103, CD123	+	Variable
Annexin	+	–
<i>BRAF</i> V600E mutation	+	–
Splenomegaly	+	+
Response to purine analogues	Good	Poor

HCL, hairy cell leukaemia; HCL-V, HCL variant.

repertoires or stereotypes in HCL [9–11]. In 2011, Tiacci et al. [12] reported the presence of the V600E mutation of the *BRAF* gene in exon 15 in all 47 investigated HCL cases. The mutation rarely occurs in exon 11. The *BRAF* mutation leads to the activation of the *RAF/MEK-ERK* pathway, resulting in enhanced cell proliferation and survival. These results have been validated by other groups and new simpler and more sensitive methods to detect the mutation, such as quantitative real-time polymerase chain reaction (q-PCR) have been developed. This finding is relevant to the diagnosis and pathogenesis of HCL with potential therapeutic implications. In the near future, testing for this mutation may be incorporated on a routine basis into the diagnostic work-up of HCL [II, C]. Although HCL-V patients lack the *BRAF* mutation, *TP53* mutations are present in one-third of cases [13].

staging and risk stratification

There is no worldwide accepted staging system for HCL. In addition to the diagnostic tests on the blood and bone marrow trephine biopsy, a staging work-up should include full blood cell counts with differential and reticulocytes, renal and liver biochemistry, serum immunoglobulins, β_2 microglobulin, direct antiglobulin test (DAT), Coombs test and hepatitis virus B and C and human immunodeficiency virus screening. Computed tomography (CT) imaging is desirable at the time of diagnosis (as around 10% of HCL patients have abdominal lymphadenopathy) and should be performed at relapse [14].

There is no international prognostic system for risk stratification of HCL. Clinical variables that have been considered to have an adverse prognosis include the degree of cytopenias (Hb < 10 g/dl, platelets < $100 \times 10^9/l$) and neutrophils (< $1 \times 10^9/l$),

as well as the presence of lymphadenopathy, which predicts a poor response to purine analogues [15]. Patients who achieve a complete response (CR) have a significantly longer disease-free survival than those who achieve a partial response (PR) [II, B] [16]. Biological factors that have been associated with a poor outcome are the presence of *TP53* mutations and the lack of somatic mutations in the *IGVH* genes, which occur in a minor proportion of cases [IV, C] [10] and the *VH4-34* family usage, a feature more frequent in HCL-V [11]. The presence of *TP53* mutations (but not *VH4-34*) usage appears to be an adverse prognostic factor in HCL-V [IV, C] [13].

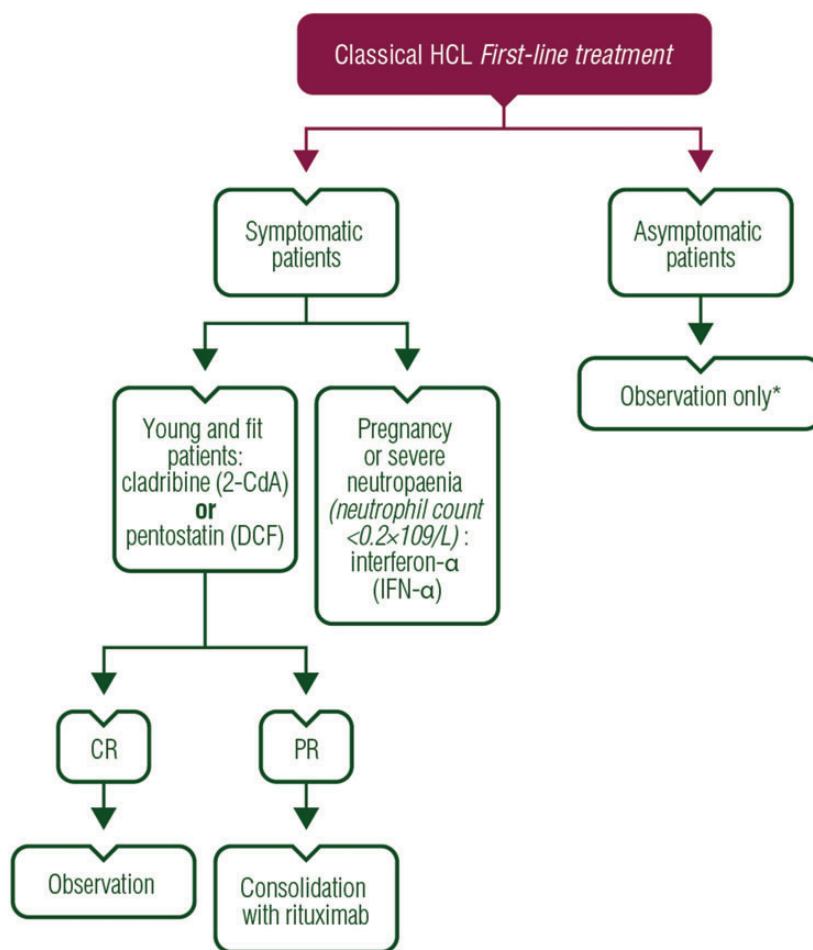
treatment plan

Treatment is not indicated in asymptomatic patients [V, B]. However, untreated patients should be closely monitored with a complete history, physical examination, and complete blood cell count with a differential test every 3–6 months. In contrast to chronic lymphocytic leukaemia, asymptomatic patients, who may be diagnosed by chance, are rare and in practice most patients need treatment shortly after diagnosis, either because of symptoms or to correct cytopenias including monocytopenia. Treatment should be initiated in patients with symptomatic disease manifested by bulky or progressive, symptomatic splenomegaly cytopenias (haemoglobin < 10 g/dl and/or platelets < $100 \times 10^9/l$ and/or neutrophils < $1 \times 10^9/l$), recurrent or severe infections and/or systemic symptoms [II, A] [17, 18].

first line

purine analogues

Purine analogues, cladribine (2-CldA) or pentostatin (DCF), are recommended as initial treatment of symptomatic HCL patients who are young and fit (Figure 1) [II, A]. 2-CldA induces durable and unmaintained response in 87%–100% patients, including CR in 85%–91%, after a single course of therapy [19]. 2-CldA is administered either as a continuous intravenous (i.v.) infusion at a dose of 0.09 mg/kg over a 5–7 day period, or as a 2-h i.v. infusion at a dose of 0.12–0.14 mg/kg for 5–7 days [20, 21]. 2-CldA is also an effective drug when administered at a dose of 0.12–0.15 mg/kg in 2-h infusion once a week over 6 courses [I, B] [22, 23]. Both CR and overall response (OR) rates are similar in weekly and daily administration. Neither less frequent infections nor haematological toxicity have been confirmed in the weekly schedule by randomised trials [I, B] [23, 24]. Similar results were achieved when the drug was given as a subcutaneous injection [II, B] [24, 25]. A subcutaneous 2-CldA is given at a dose of 0.1 mg/kg/day for 5–7 days or 0.14 mg/kg/day for 5 days as a single course [24, 25]. Grade 3–4 toxicity, largely represented by neutropenic fevers and infections, were less frequent when lower total doses were used (0.5 mg/kg) than higher doses (0.7 mg/kg) with similar OR [25]. Subcutaneous administration does not usually require hospitalisation, and seems to be an easier way of delivering the drug than i.v. administration. Although no randomised trial comparing i.v. versus subcutaneous 2-CldA administration has been performed, the efficacy of both methods is similar [II, B]. A CR following 2-CldA administration is durable even without maintenance therapy [16]. In patients demonstrating a



* in practice, most patients need treatment shortly after diagnosis either because of symptoms and to correct cytopaenia

Figure 1. Therapeutic algorithm for newly diagnosed classical hairy cell leukaemia (HCL). CR, complete response; PR, partial response.

PR after the first course of 2-CldA, a second course should be repeated to achieve a CR at least 6 months after the end of the first course, with or without rituximab [IV, B] [26].

Similarly to 2-CldA, DCF induces a high rate of long-lasting CR. In patients with a normal creatinine clearance (>60 ml/min), DCF is usually given at a dose of 4 mg/m^2 i.v. every second week until CR, plus one or two consolidating injections [27]. After 8–9 courses, the full blood count usually normalises, and the bone marrow biopsy should be performed to confirm a CR [III, B]. If a CR is documented, one or two further DCF injections are indicated [16]. DCF and 2-CldA appear to induce similar high response rates, duration of response, recurrence rates and adverse events [III, B] [16]. However, no randomised, direct comparison between the two drugs has been performed. The advantage of DCF over interferon- α (IFN- α) in HCL patients has been confirmed in a multicentre, randomised trial [I, A] [28]. 2-CldA administration is more convenient than DCF and is used more frequently.

interferon- α

As purine analogues produce higher and more durable remissions, and are more convenient to patients, the use of IFN- α in

the treatment of HCL is limited. However, IFN- α may still have a place in the treatment of HCL in pregnancy [V, B]. It can also be used in patients presenting with very severe neutropaenia (neutrophil count $<0.2 \times 10^9/l$) to increase the neutrophil count prior to nucleoside analogue therapy [V, C] [29].

response evaluation

Responses are defined according to the ‘Consensus Resolution’ criteria (Table 3) [30]. Response evaluation includes careful physical examination and a blood cell count. A marrow biopsy is recommended to establish a CR. A chest X-ray and an abdominal ultrasound or CT for response evaluation should be performed. A CR requires the morphological absence of hairy cells in peripheral blood and bone marrow aspiration or biopsy specimens, and normalisation of any organomegaly and cytopaenia. Immunophenotypic analysis of peripheral blood or bone marrow is not required but is useful to detect MRD. A PR is defined as normalisation of peripheral counts, associated with at least a 50% reduction in organomegaly and bone marrow hairy cells, and $<5\%$ circulating hairy cells. All other outcomes are considered as nonresponse. The eradication of MRD is generally not recommended in routine clinical practice. Assessment of response

Table 3. Response criteria for HCL

	Definition of response categories
Complete response	No hairy cells on peripheral blood and bone marrow aspiration or biopsy specimens, normalisation of organomegaly and peripheral blood counts
Partial response	Normalisation of peripheral blood counts, at least 50% reduction in organomegaly and bone marrow hairy cells, and <5% circulating hairy cells
Relapse	Any deterioration in blood counts related to the detection of hairy cells in peripheral blood and/or bone marrow and/or increasing splenomegaly

HCL, hairy cell leukaemia. Data from [30].

should be performed 4–6 months after treatment with 2-CldA and after 8–9 courses of DCF [31]. Relapse is defined as any deterioration in blood counts related to the detection of hairy cells in peripheral blood and/or bone marrow.

treatment of relapsed patients and patients refractory to purine analogues

Relapsed patients can be successfully retreated with 2-CldA or DCF if relapse occurs after 12–18 months [IV, B] [32] (Figure 2). The alternative nucleoside analogue can be used in early relapse within 2 years after the first-line treatment [31]. The ability to attain CR decreases with each course of therapy, but CR duration appears to be similar after first-, second- or third-line therapy [16, 33].

Rituximab at a dose of 375 mg/m² for 4–8 doses given weekly as i.v. infusions can be used in early relapsed patients [III, B] [34–36]. However, rituximab alone is inferior to purine analogues and is not the treatment of choice as a single agent in relapsed patients. Outcomes for patients with recurrent HCL appear to be better when a combination of rituximab and 2-CldA or DCF is used rather than the purine analogue alone [III, B] [37, 38]. Concurrent therapy of rituximab and a purine analogue induces higher response rates, and higher rates of toxic events than in the sequential administration [III, B] [39].

IFN- α is also a possible option for selected patients relapsing after purine analogue therapy [IV, B] [40, 41]. Patients refractory to purine analogue therapy should be enrolled on clinical trials that use new agents, whenever possible. Fludarabine at a dose of 40 mg/m² oral (p.o.) for five consecutive days in combination with an i.v. injection of 375 mg/m² rituximab on day 1, every 28 days for four cycles, can be a therapeutic option in relapsed or refractory patients previously treated with 2-CldA [IV, B]. After a median follow-up of 35 months with 14 progression-free patients, a 5-year progression-free survival (PFS) of 89%, an overall survival (OS) of 83% and a recurrence rate of 7% were observed in 15 treated patients [42]. Bendamustine at 70–90 mg/m² combined with rituximab is another therapeutic option in multiply relapsed/refractory HCL, and could be considered in HCL patients after the failure of standard therapies [IV, B] [43].

Other promising drugs active in purine analogue refractory HCL patients include moxetumomab pasudotox, an anti-CD22 recombinant immunotoxin, and vemurafenib, a *BRAF* V600E inhibitor [44–46]. A phase I trial of moxetumomab pasudotox in relapsed/refractory HCL induced an 86% OR rate, and a 46% CR [44]. However, moxetumomab pasudotox is not licensed in Europe yet.

Vemurafenib also showed remarkable activity in multiply relapsed and refractory HCL patients with rapidly decreased splenomegaly, increased platelet counts and normalisation of haemoglobin and granulocyte counts [45, 46]. The optimal dosing and duration of treatment using vemurafenib is unknown. A multicentre, phase II study of vemurafenib in the treatment of refractory HCL is ongoing (NCT01711632). The therapeutic potential of the Bruton's tyrosine kinase (BTK) inhibitor ibrutinib also needs to be taken into consideration in a relapse setting, given the proven *in vitro* activity of this drug in hairy cells [47]. A phase II study with ibrutinib in patients with relapsed HCL is ongoing (NCT01841723).

splenectomy

Splenectomy may be indicated in patients with resistant massive symptomatic splenomegaly (>10 cm below the costal margin) with accompanied low-level bone marrow infiltration [IV, B] [48]. OR rates of 60%–100% were documented in eight major reports [29]. Splenectomised patients respond better and faster to the subsequent chemotherapy [V, B]. Splenectomy can also be considered when progressive HCL develops during pregnancy and in patients refractory to nucleoside analogues and IFN- α [V, B] [29]. Systemic therapy should not be performed earlier than 6 months after splenectomy to reach full benefits of this treatment [31]. Vaccination against *Haemophilus influenzae* and pneumococcus before splenectomy is recommended [IV, B] [49].

allogeneic stem cell transplantation

Allogeneic stem cell transplantation has a potential role in younger, heavily pretreated HCL patients who have had multiple relapses and are refractory to purine analogues and rituximab [V, C] [50, 51].

treatment during pregnancy

Only a few cases of HCL during pregnancy have been reported [52, 53]. Treatment is indicated only when truly warranted. The appropriate therapy depends on the stage of pregnancy, rate of disease progression and response to previous therapies. If treatment is indicated, the lower risks associated with IFN- α for both the mother and the fetus make it the treatment of choice [V, B]. IFN- α shows good tolerance, uncomplicated pregnancy and delivery, and normal child development [54]. Splenectomy is another option to consider, should IFN- α fail, especially in early gestation when the risks are lower [V, B] [52, 55]. Administration of 2-CldA and rituximab are not indicated in pregnancy because of the risk of teratogenic effects. However, successful pregnancy after the administration of 2-CldA and rituximab has also been reported [56].

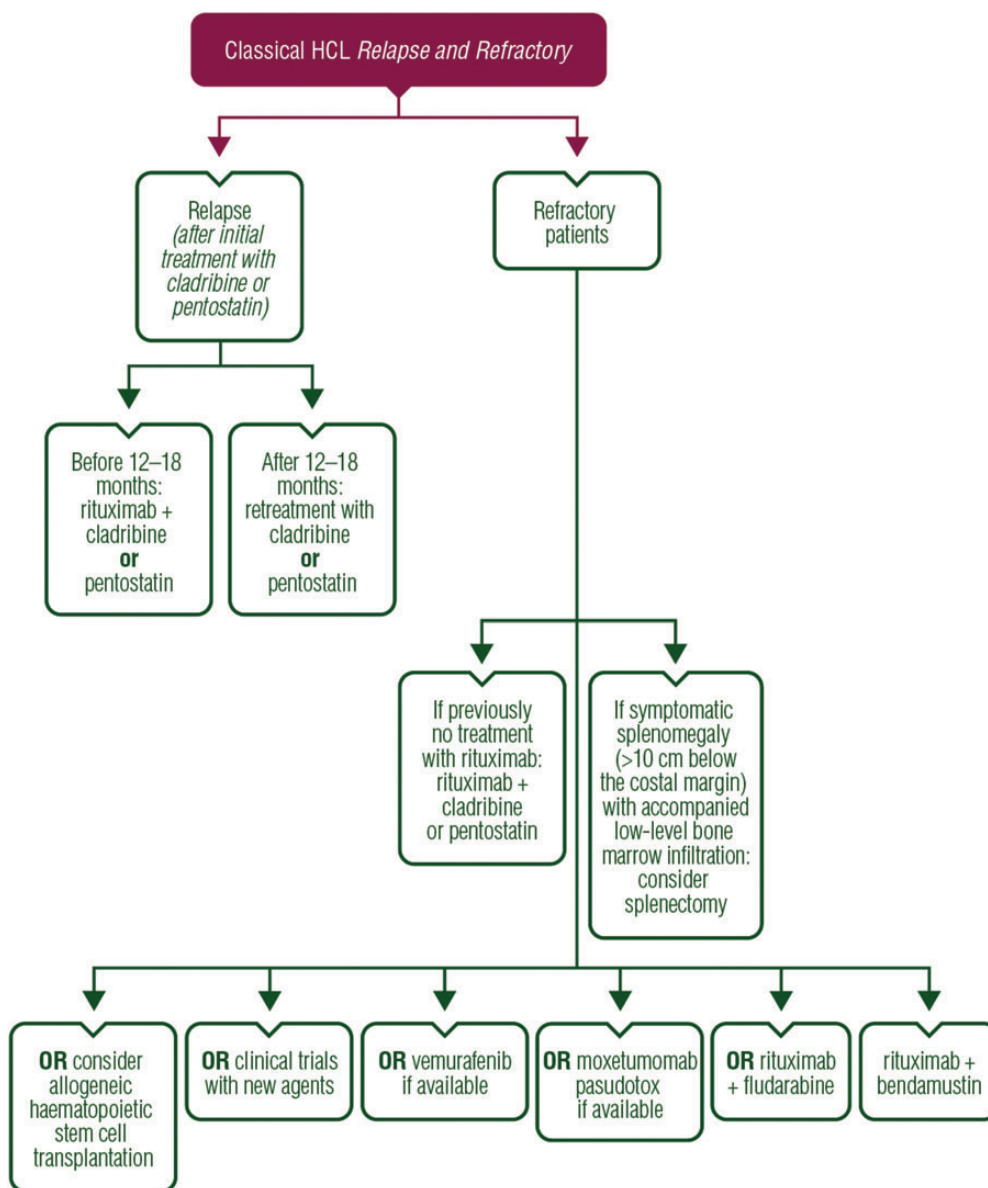


Figure 2. Therapeutic algorithm for relapsed and refractory classical hairy cell leukaemia (HCL).

supportive treatment

Patients treated with nucleoside analogues and lymphopaenia should receive prophylactic co-trimoxazole 960 mg three times per week and aciclovir (200 mg three times daily) until the lymphocyte count increases to $>1 \times 10^9/l$ to prevent pneumocystis infections and herpes reactivation [IV, B]. Co-trimoxazole and aciclovir prophylaxis should be started one week after purine analogue administration to reduce allergic skin reaction [18]. The routine adjunctive use of filgrastim with 2-CldA in the treatment of patients with HCL and severe neutropaenia is not recommended [IV, C] [57]. However, granulocyte colony-stimulating factor use should be considered in individual cases with severe neutropaenia and life-threatening infection. Patients treated with 2-CldA or DCF should receive irradiated blood products to prevent transfusion-associated graft-versus-host disease [58].

treatment of HCL-V

The results of the treatment of HCL-V with purine analogues are poor (Figure 3). The analysis of 19 cases treated with 2-CldA showed a response rate of 55%, including only 2 with CR [59]. In addition, the majority of HCL-V patients required more than 1 cycle to maintain a response. DCF induced a PR in only 8 out of 15 (54%) patients and no CR was achieved [60]. Rituximab alone, or splenectomy followed by rituximab therapy, can also induce CR in HCL-V [61, 62]. However, administration of 2-CldA immediately followed by rituximab, typically involving 2-CldA being given at a dose of 0.15 mg/kg on days 1–5, with 8 weekly doses of 375 mg/m² rituximab beginning day 1, appears to be more effective than 2-CldA alone or rituximab alone and should be considered as the initial treatment of HCL-V patients [IV, B] [38, 63]. In a recent study based on 8 patients,

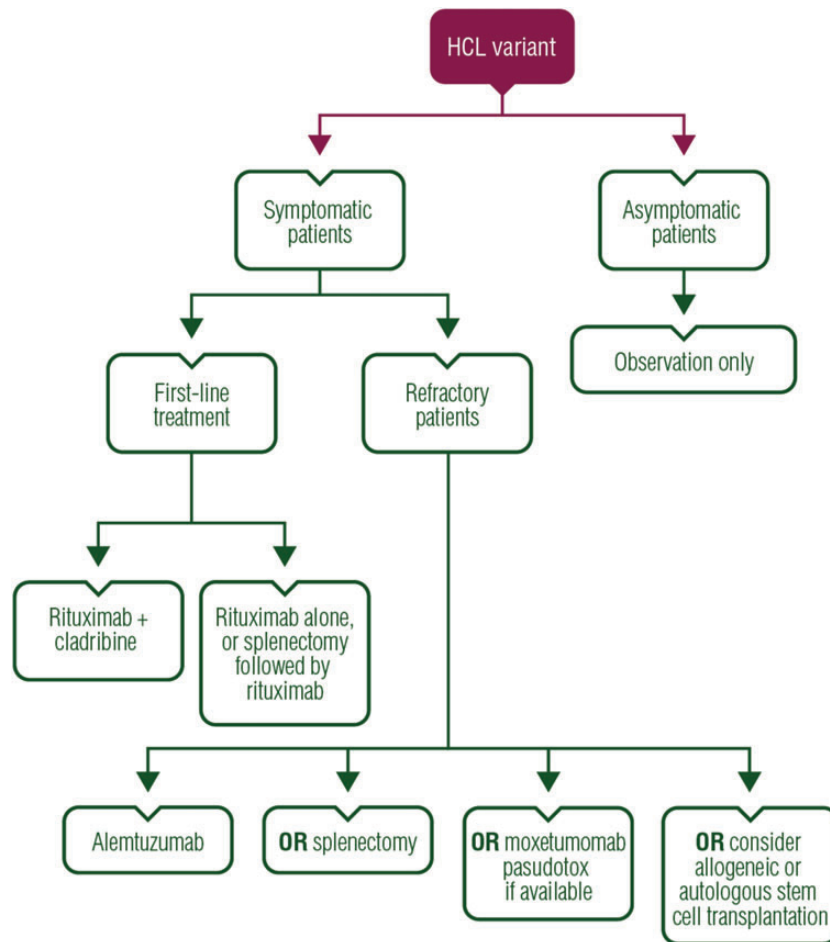


Figure 3. Therapeutic algorithm for hairy cell leukaemia variant (HCL-V).

all achieved a CR, including 7 (88%) with MRD negativity at 12–38 (median 24) months of follow-up. Alternatively, individual case reports suggest that alemtuzumab is an active agent in treating HCL-V, even in patients who have relapsed after rituximab [64]. Splenectomy induces clinical responses in some patients with HCL-V, and is recommended because it corrects cytopenias, removes the bulk of the tumour and may improve response to purine nucleoside analogues [V, B] [65]. Splenic irradiation could be performed in elderly patients with a high surgical risk of splenectomy [V, B]. Clinical case reports support the use of moxetumomab pasudotox in patients with HCL-V [V, B] [44]. Some case reports indicate that autologous or allogeneic hematopoietic cell transplantation can be effective in refractory patients [V, B] [66]. However, the data to support these approaches are limited.

personalised medicine

In HCL and HCL-V, more research is needed to identify biomarkers which could be used for medical treatment decisions. Recently, *BRAF* V600E mutation has been identified as a characteristic biomarker of HCL [III, B] [67–69]. It is present in nearly all cases of HCL but virtually absent in diseases that mimic HCL. In a recent study, a *BRAF* V600E mutation was detected

in 17 (77.3%) of 22 HCL cases by PCR, and was demonstrated in 20 (90.9%) cases using VE1 immunohistochemistry staining [68]. Immunohistochemical detection of *BRAF* V600E mutant protein is highly sensitive and specific for the diagnosis of HCL.

follow-up and long-term implications

A follow-up of asymptomatic patients should include a complete history, physical examination, a blood cell count and routine chemistry every 3–12 months [II, B]. Regular CT scans are not necessary outside clinical trials. The frequency of second malignancies is increased in HCL patients whether treated or untreated. Solid and haematological malignancies develop in 10% of patients after HCL diagnosis, particularly chronic lymphoproliferative diseases (myeloma, Hodgkin's and non-Hodgkin's lymphoma), melanoma and thyroid cancer [70, 71].

methodology

These clinical practice guidelines were developed in accordance with the ESMO standard operating procedures for clinical practice guidelines development. The relevant literature has been selected by the expert authors. Levels of evidence and grades of recommendation have been applied using the system shown in

Table 4. Levels of evidence and grades of recommendation (adapted from the Infectious Diseases Society of America-United States Public Health Service Grading System)^a

Levels of evidence	
I	Evidence from at least one large randomised, controlled trial of good methodological quality (low potential for bias) or meta-analyses of well-conducted randomised trials without heterogeneity
II	Small randomised trials or large randomised trials with a suspicion of bias (lower methodological quality) or meta-analyses of such trials or of trials with demonstrated heterogeneity
III	Prospective cohort studies
IV	Retrospective cohort studies or case-control studies
V	Studies without control group, case reports, experts opinions
Grades of recommendation	
A	Strong evidence for efficacy with a substantial clinical benefit, strongly recommended
B	Strong or moderate evidence for efficacy but with a limited clinical benefit, generally recommended
C	Insufficient evidence for efficacy or benefit does not outweigh the risk or the disadvantages (adverse events, costs, ...), optional
D	Moderate evidence against efficacy or for adverse outcome, generally not recommended
E	Strong evidence against efficacy or for adverse outcome, never recommended

^aBy permission of the Infectious Diseases Society of America [72].

Table 4. Statements without grading were considered justified standard clinical practice by the experts and the ESMO faculty. This manuscript has been subjected to an anonymous peer review process.

conflict of interest

TR has reported honoraria from Roche and research grants from Roche, Janssen, GlaxoSmithKline and Medimmune. PLZ has reported honoraria from Takeda Millennium, Roche, Celgene, Pfizer, Gilead and Sandoz. CB has reported honoraria from Roche, Pfizer, Celgene, Pharmacyclics and Janssen and research grants from Roche and Janssen. The other authors have reported no potential conflicts of interest.

references

- Ferlay J, Steliarova-Foucher E, Lortet-Tieulent J et al. Cancer incidence and mortality patterns in Europe: estimates for 40 countries in 2012. *Eur J Cancer* 2013; 49: 1374–1403.
- Morton LM, Wang SS, Devesa SS et al. Lymphoma incidence patterns by WHO subtype in the United States, 1992–2001. *Blood* 2006; 107: 265–276.
- Grever MR, Blachly JS, Andritsos LA. Hairy cell leukemia: update on molecular profiling and therapeutic advances. *Blood Rev* 2014; 28: 197–203.
- Swerdlow SH, Campo E, Harris NL et al. World Health Organization (WHO) Classification of Tumours: Pathology and Genetics of Haematopoietic and Lymphatic Tissues. 4th edition. Lyon, France: IARC Press, 2008.
- Del Giudice I, Matutes E, Morilla R et al. The diagnostic value of CD123 in B-cell disorders with hairy or villous lymphocytes. *Haematologica* 2004; 89: 303–308.
- Matutes E. Immunophenotyping and differential diagnosis of hairy cell leukemia. *Hematol Oncol Clin North Am* 2006; 20: 1051–1063.
- Pillai V, Pozdnyakova O, Charest K et al. CD200 flow cytometric assessment and semiquantitative immunohistochemical staining distinguishes hairy cell leukemia from hairy cell leukemia-variant and other B-cell lymphoproliferative disorders. *Am J Clin Pathol* 2013; 140: 536–543.
- Andrulis M, Penzel R, Weichert W et al. Application of a BRAF V600E mutation-specific antibody for the diagnosis of hairy cell leukemia. *Am J Surg Pathol* 2012; 36: 1796–1800.
- Hockley SL, Giannouli S, Morilla A et al. Insight into the molecular pathogenesis of hairy cell leukaemia, hairy cell leukaemia variant and splenic marginal zone lymphoma provided by the analysis of their *IGH* rearrangements and somatic hypermutation patterns. *Br J Haematol* 2010; 148: 666–669.
- Forconi F, Sozzi E, Cencini E et al. Hairy cell leukemias with unmutated IGHV genes define the minor subset refractory to single-agent cladribine and with more aggressive behaviour. *Blood* 2009; 114: 4696–4702.
- Arons E, Suntum T, Stetler-Stevenson M, Kreitman RJ. VH4–34+ hairy cell leukemia, a new variant with poor prognosis despite standard therapy. *Blood* 2009; 114: 4687–4695.
- Tiacci E, Trifonov V, Schiavoni G et al. BRAF mutations in hairy cell leukemia. *N Engl J Med* 2011; 364: 2305–2315.
- Hockley SL, Else M, Morilla A et al. The prognostic impact of clinical and molecular features in hairy cell leukaemia variant and splenic marginal zone lymphoma. *Br J Haematol* 2012; 158: 347–354.
- Merciecia J, Puga M, Matutes E et al. Incidence and significance of abdominal lymphadenopathy in hairy cell leukaemia. *Leuk Lymphoma* 1994; 14(Suppl. 1): 79–83.
- Merciecia J, Matutes E, Emmett E et al. 2-chlorodeoxyadenosine in the treatment of hairy cell leukaemia: differences in response in patients with and without abdominal lymphadenopathy. *Br J Haematol* 1996; 93: 409–411.
- Else M, Dearden CE, Matutes E et al. Long-term follow-up of 233 patients with hairy cell leukaemia, treated initially with pentostatin or cladribine, at a median of 16 years from diagnosis. *Br J Haematol* 2009; 145: 733–740.
- Grever MR. How I treat hairy cell leukemia. *Blood* 2010; 115: 21–28.
- Cornet E, Delmer A, Feugier P et al. Recommendations of the SFH (French Society of Haematology) for the diagnosis, treatment and follow-up of hairy cell leukaemia. *Ann Hematol* 2014; 93: 1977–1983.
- Saven A, Burian C, Koziol JA, Piro LD. Long-term follow-up of patients with hairy cell leukemia after cladribine treatment. *Blood* 1998; 92: 1918–1926.
- Cheson BD, Sorensen JM, Vena DA et al. Treatment of hairy cell leukemia with 2-chlorodeoxyadenosine via the Group C protocol mechanism of the National Cancer Institute: a report of 979 patients. *J Clin Oncol* 1998; 16: 3007–3015.
- Robak T, Blasińska-Morawiec M, Krykowski E et al. 2-chlorodeoxyadenosine (2-CdA) in 2-hour versus 24-hour intravenous infusion in the treatment of patients with hairy cell leukemia. *Leuk Lymphoma* 1996; 22: 107–111.
- Robak T, Jamrozik K, Gora-Tybor J et al. Cladribine in a weekly versus daily schedule for untreated active hairy cell leukemia: final report from the Polish Adult Leukemia Group (PALG) of a prospective, randomized, multicenter trial. *Blood* 2007; 109: 3672–3675.
- Zenhäusern R, Schmitz SF, Solenthaler M et al. Randomized trial of daily versus weekly administration of 2-chlorodeoxyadenosine in patients with hairy cell leukemia: a multicenter phase III trial (SAKK 32/98). *Leuk Lymphoma* 2009; 50: 1501–1511.

24. von Rohr A, Schmitz SF, Tichelli A et al. Treatment of hairy cell leukemia with cladribine (2-chlorodeoxyadenosine) by subcutaneous bolus injection: a phase II study. *Ann Oncol* 2002; 13: 1641–1649.
25. Lauria F, Cencini E, Forconi F. Alternative methods of cladribine administration. *Leuk Lymphoma* 2011; 52(Suppl. 2): 34–37.
26. Dearden CE, Else M, Catovsky D. Long-term results for pentostatin and cladribine treatment of hairy cell leukemia. *Leuk Lymphoma* 2011; 52(Suppl. 2): 21–24.
27. Flinn IW, Kopecky KJ, Foucar MK et al. Long-term follow-up of remission duration, mortality and second malignancies in hairy cell leukemia patients treated with pentostatin. *Blood* 2000; 96: 2981–2986.
28. Grever M, Kopecky K, Foucar MK et al. Randomized comparison of pentostatin versus interferon alfa-2a in previously untreated patients with hairy cell leukemia: an intergroup study. *J Clin Oncol* 1995; 13: 974–982.
29. Habermann TM, Rai K. Historical treatments of hairy cell leukemia, splenectomy and interferon: past and current uses. *Leuk Lymphoma* 2011; 52(Suppl. 2): 18–20.
30. Anonymous. Consensus resolution: proposed criteria for evaluation of response to treatment in hairy cell leukemia. *Leukemia* 1987; 1: 405.
31. Jones G, Parry-Jones N, Wilkins B et al. Revised guidelines for the diagnosis and management of hairy cell leukaemia and hairy cell leukaemia variant. *Br J Haematol* 2012; 156: 186–195.
32. Naik RR, Saven A. My treatment approach to hairy cell leukemia. *Mayo Clin Proc* 2012; 87: 67–76.
33. Zinzani PL, Pellegrini C, Stefoni V et al. Hairy cell leukemia: evaluation of the long-term outcome in 121 patients. *Cancer* 2010; 116: 4788–4792.
34. Hagberg H, Lundholm L. Rituximab, a chimaeric anti-CD20 monoclonal antibody in the treatment of hairy cell leukaemia. *Br J Haematol* 2001; 115: 609–611.
35. Nieva J, Bethel K, Saven A. Phase 2 study of rituximab in the treatment of cladribine-failed patients with hairy cell leukemia. *Blood* 2003; 102: 810–813.
36. Forconi F, Toraldo F, Sozzi E et al. Complete molecular remission induced by concomitant cladribine-rituximab treatment in a case of multi-resistant hairy cell leukemia. *Leuk Lymphoma* 2007; 48: 2441–2443.
37. Else M, Dearden CE, Matutes E et al. Rituximab with pentostatin or cladribine: an effective combination treatment for hairy cell leukemia after disease recurrence. *Leuk Lymphoma* 2011; 52(Suppl. 2): 75–78.
38. Ravandi F, O'Brien S, Jorgensen J et al. Phase 2 study of cladribine followed by rituximab in patients with hairy cell leukemia. *Blood* 2011; 118: 3818–3823.
39. Else M, Osuji N, Forconi F et al. The role of rituximab in combination with pentostatin or cladribine for the treatment of recurrent/refractory hairy cell leukemia. *Cancer* 2007; 110: 2240–2247.
40. Seymour JF, Estey EH, Keating MJ, Kurzrock R. Response to interferon-alpha in patients with hairy cell leukemia relapsing after treatment with 2-chlorodeoxyadenosine. *Leukemia* 1995; 9: 929–932.
41. Hoffman MA. Interferon-alpha is a very effective salvage therapy for patients with hairy cell leukemia relapsing after cladribine: a report of three cases. *Med Oncol* 2011; 28: 1537–1541.
42. Gerrie AS, Zypchen LN, Connors JM. Fludarabine and rituximab for relapsed or refractory hairy cell leukemia. *Blood* 2012; 119: 1988–1991.
43. Burotto M, Stetler-Stevenson M, Arons E et al. Bendamustine and rituximab in relapsed and refractory hairy cell leukemia. *Clin Cancer Res* 2013; 19: 6313–6321.
44. Kreitman RJ, Tallman MS, Robak T et al. Phase I trial of anti-CD22 recombinant immunotoxin moxetumomab pasudotox (CAT-8015 or HA22) in patients with hairy cell leukemia. *J Clin Oncol* 2012; 30: 1822–1828.
45. Tiacci E, De Carolis L, Zinzani PL et al. Vemurafenib is safe and highly active in hairy cell leukemia patients refractory to or relapsed after purine analogs: a phase-2 Italian clinical trial. *Haematologica* 2014; 99(s1): Abstract S696.
46. Samuel J, Macip S, Dyer MJ. Efficacy of vemurafenib in hairy-cell leukemia. *N Engl J Med* 2014; 370: 286–288.
47. Sivina M, Kreitman RJ, Arons E et al. The bruton tyrosine kinase inhibitor ibrutinib (PCI-32765) blocks hairy cell leukaemia survival, proliferation and B cell receptor signalling: a new therapeutic approach. *Br J Haematol* 2014; 166: 177–188.
48. Jansen J, Hermans J. Splenectomy in hairy cell leukemia: a retrospective multicenter analysis. *Cancer* 1981; 47: 2066–2076.
49. Davies JM, Barnes R, Milligan D; British Committee for Standards in Haematology. Working Party of the Haematology/Oncology Task Force. Update of guidelines for the prevention and treatment of infection in patients with an absent or dysfunctional spleen. *Clin Med* 2002; 2: 440–443.
50. Zinzani PL, Bonifazi F, Pellegrini C et al. Hairy cell leukemia: allogeneic transplantation could be an optimal option in selected patients. *Clin Lymphoma Myeloma Leuk* 2012; 12: 287–289.
51. Kiyasu J, Shiratsuchi M, Ohtsuka R et al. Achievement of complete remission of refractory hairy cell leukemia by rituximab progressing after allogeneic hematopoietic stem cell transplantation. *Int J Hematol* 2009; 89: 403–405.
52. Stiles GM, Stanco LM, Saven A, Hoffmann KD. Splenectomy for hairy cell leukemia in pregnancy. *J Perinatol* 1998; 18: 200–201.
53. Orłowski RZ. Successful pregnancy after cladribine therapy for hairy cell leukemia. *Leuk Lymphoma* 2004; 45: 187–188.
54. Baer MR, Ozer H, Foon KA. Interferon-alpha therapy during pregnancy in chronic myelogenous leukaemia and hairy cell leukaemia. *Br J Haematol* 1992; 81: 167–169.
55. Adeniji BA, Fallas M, Incerpi M et al. Laparoscopic splenectomy for hairy cell leukemia in pregnancy. *Case Rep Med* 2010; 2010: 136823.
56. Daver N, Nazha A, Kantarjian HM et al. Treatment of hairy cell leukemia during pregnancy: are purine analogues and rituximab viable therapeutic options. *Clin Lymphoma Myeloma Leuk* 2013; 13: 86–89.
57. Saven A, Burian C, Adusumalli J, Koziol JA. Filgrastim for cladribine-induced neutropenic fever in patients with hairy cell leukemia. *Blood* 1999; 93: 2471–2477.
58. Treleaven J, Gennery A, Marsh J et al. Guidelines on the use of irradiated blood components prepared by the British Committee for Standards in Haematology blood transfusion task force. *Br J Haematol* 2011; 152: 35–51.
59. Robak T. Hairy-cell leukemia variant: recent view on diagnosis, biology and treatment. *Cancer Treat Rev* 2011; 37: 3–10.
60. Matutes E, Wotherspoon A, Catovsky D. The variant form of hairy-cell leukaemia. *Best Pract Res Clin Haematol* 2003; 16: 41–56.
61. Narat S, Gandla J, Dogan A, Mehta A. Successful treatment of hairy cell leukemia variant with rituximab. *Leuk Lymphoma* 2005; 46: 1229–1232.
62. Yoshida T, Mihara K, Sugihara S et al. Splenectomy followed by administration of rituximab is useful to treat a patient with hairy cell leukemia-variant. *Ann Hematol* 2013; 92: 711–713.
63. Kreitman RJ, Wilson W, Calvo KR et al. Cladribine with immediate rituximab for the treatment of patients with variant hairy cell leukemia. *Clin Cancer Res* 2013; 19: 6873–6881.
64. Telek B, Batár P, Udvardy M. Successful alemtuzumab treatment of a patient with atypical hairy cell leukaemia variant. *Orv Hetil* 2007; 148: 1805–1807.
65. Zinzani PL, Lauria F, Buzzi M et al. Hairy cell leukemia variant: A morphologic, immunologic and clinical study of 7 cases. *Haematologica* 1990; 75: 54–57.
66. Busemann C, Schüller F, Krüger W et al. Late extramedullary relapse after allogeneic transplantation in a case of variant hairy cell leukaemia. *Bone Marrow Transplant* 2010; 45: 1117–1118.
67. Uppal G, Ly V, Wang ZX et al. The utility of BRAF V600E mutation-specific antibody VE1 for the diagnosis of hairy cell leukemia. *Am J Clin Pathol* 2015; 143: 120–125.
68. Brown NA, Betz BL, Weigelin HC et al. Evaluation of allele-specific PCR and immunohistochemistry for the detection of BRAF V600E mutations in hairy cell leukemia. *Am J Clin Pathol* 2015; 143: 89–99.
69. Wang XJ, Kim A, Li S. Immunohistochemical analysis using a BRAF V600E mutation specific antibody is highly sensitive and specific for the diagnosis of hairy cell leukemia. *Int J Clin Exp Pathol* 2014; 7: 4323–4328.
70. Cornet E, Tomowiak C, Tanguy-Schmidt A et al. Long-term follow-up and second malignancies in 487 patients with hairy cell leukaemia. *Br J Haematol* 2014; 166: 390–400.
71. Hisada M, Chen BE, Jaffe ES, Travis LB. Second cancer incidence and cause-specific mortality among 3104 patients with hairy cell leukemia: a population-based study. *J Natl Cancer Inst* 2007; 99: 215–222.
72. Dykewicz CA. Summary of the guidelines for preventing opportunistic infections among hematopoietic stem cell transplant recipients. *Clin Infect Dis* 2001; 33: 139–144.