*Annals of Oncology* 24 (Supplement 6): vi115–vi124, 2013
doi:10.1093/annonc/mdt286
Published online 23 August 2013

# Penile cancer: ESMO Clinical Practice Guidelines for diagnosis, treatment and follow-up†

H. Van Poppel[1], N. A. Watkin[2], S. Osanto[3], L. Moonen[4], A. Horwich[5] & V. Kataja[6], on behalf of the ESMO Guidelines Working Group*

[1]Department of Urology, University Hospital, KU Leuven, Leuven, Belgium; [2]Department of Urology, St. George's Hospital, London, UK; [3]Department of Oncology, Leiden University Medical Centre, Leiden; [4]Department of Radiation Oncology, The Netherlands Cancer Institute, Antoni van Leeuwenhoek Hospital, Amsterdam, The Netherlands; [5]Institute of Cancer Research and Royal Marsden Hospital, Sutton, UK; [6]Cancer Centre, Kuopio University Hospital, Kuopio, Finland

These Clinical Practice Guidelines are endorsed by the Japanese Society of Medical Oncology (JSMO)

## incidence

Penile cancer is an uncommon malignancy in Western countries with an incidence of <1 per 100 000 men in Europe and the United States but is more frequent in Africa, Asia and South America and accounts for 10% of all cancers in men in certain areas. Incidence varies according to racial group, ethnicity, and geographical location. Important risk factors include social and cultural habits, and hygienic and religious practices. Penile cancer is rare in circumcised men, particularly if they are circumcised as newborns. Penile cancer in men and cervical cancer in women have a strong correlation with human papilloma virus (HPV) infection [1, 2].

## diagnosis

Accurate histological diagnosis and staging of both the primary tumour and regional nodes are of utmost importance for selecting appropriate therapy. Penile cancer drains primarily to the inguinal nodes. The diagnosis of the primary tumour, the inguinal lymph nodes (LNs) and regional and distant metastases are discussed in Table 1. An incisional or excisional biopsy is advised. Punch biopsy or scrapings may not be sufficiently representative.

### primary tumour

With regard to the primary tumour, the initial assessment should be made by physical examination. The physical examination of suspected penile cancer must record: diameter of penile lesion(s) or suspicious areas; location of lesion(s) on the penis; number of lesions; morphology of lesion(s): papillary, nodular, ulcerous or flat; relationship of lesion(s) to other structures, e.g. submucosa, tunica albuginea, urethra, corpus spongiosum and corpus cavernosum; colour and boundaries of lesion(s); and penis length. Physical examination alone can assess infiltration of the tumour into the corpora cavernosa. Where there is doubt as to the presence of corpora cavernosa invasion and to determine whether limited surgery is possible, magnetic resonance imaging (MRI) combined with an intra-cavernosal injection of prostaglandin E1 that causes an artificial erection may be helpful [1].

### regional lymph nodes

Evaluation of the LNs is also critical as characteristics such as the involvement of the inguinal LNs, the number and site of positive nodes and extracapsular nodal involvement provide the strongest prognostic factors of survival.

*non-palpable nodes.* If nodes are non-palpable (cN0) at physical examination, dynamic sentinel node biopsy (DSNB) is indicated in intermediate (T1G2) or high-risk (T1G3 or worse) disease. Early detection of LN metastases by DSNB and subsequent resection in clinically node negative T2-3 penile cancer improves survival compared with a policy of surveillance [III, C] [3]. Moreover, DSNB is a less morbid approach compared with prophylactic inguinal lymph reproducibility of the technique, for which the sentinel node identification rate was 97%, the false-negative rate was 7% and the complication rate was 4.7% [III] [4]. A recent meta-analysis of 17 studies demonstrated that DSNB is a method with a high detection rate of sentinel nodes (pooled; 88.3%) and sensitivity (pooled; 88.0%). The highest detection rate and sensitivity was seen in studies using radiotracer and blue dye for sentinel LN mapping and including only cN0 cases [II] [5]. If DSNB is not available, ultrasound-guided fine-needle aspiration cytology (FNAC) biopsy of visualised nodes can be used [1].

*palpable nodes.* If nodes are palpable, LN metastases can be diagnosed using a percutaneous FNAC biopsy and/or histology. In the case of a negative biopsy and clinically suspicious nodes, a repeat biopsy or node excision is advised [C] [6]. At the time of diagnosis, almost half of palpable inguinal nodes are enlarged due to inflammatory changes; however, those that become

*Correspondence to: ESMO Guidelines Working Group, ESMO Head Office, Via L. Taddei 4, CH-6962 Viganello-Lugano, Switzerland.
E-mail: clinicalguidelines@esmo.org

†Approved by the ESMO Guidelines Working Group: July 2013.

© The Author 2013. Published by Oxford University Press on behalf of the European Society for Medical Oncology.
All rights reserved. For permissions, please email: journals.permissions@oup.com.

**Table 1.** Guidelines on the diagnosis of penile cancer [C]

| |
|---|
| Primary tumour |
| Physical examination recording morphological and physical characteristics of the lesion |
| Cytological and/or histological diagnosis |
| Regional lymph node disease |
| Physical examination of both groins, recording morphological and physical characteristics of the nodes |
| a) Non-palpable nodes → DSNB (if not available: ultrasound-guided FNAC biopsy/risk factors) |
| b) Palpable nodes → FNAC biopsy |
| Regional metastases (inguinal and pelvic nodes) |
| Pelvic CT scan/PET-CT scan in patients with metastatic inguinal nodes |
| More distant metastases |
| PET-CT scan (if not available CT scan and chest X-ray) |
| Bone scan in symptomatic patients |
| Molecular markers |
| Investigational, currently not useful in clinical practice |

Reprinted from Pizzocaro G, et al. [1], with permission from Elsevier.
CT, computed tomography; DSNB, dynamic sentinel node biopsy; FNAC, fine-needle aspiration cytology; PET, positron emission tomography.

palpable during follow-up are malignant in nearly 100% of cases [7]. MRI and computed tomography (CT) scanning can detect enlarged inguinal and pelvic nodes. CT scan is used primarily, despite low sensitivity (36%). The use of $^{18}$F-fluorodeoxyglucose positron emission tomography-computed tomography ($^{18}$F-FDG PET/CT) remains uncertain.

### distant metastases

Scanning with $^{18}$F-FDG PET/CT appears encouraging for detection of pelvic LN metastases with great accuracy and also identifies more distant metastases in patients with inguinal node-positive penile cancer [III/IV, C] [8].

### pathological categories

Squamous cell carcinoma (SCC) accounts for more than 95% of cases of penile cancer. Bowenoid papulosis (BP), Bowen's disease (BD) and erythroplasia of Queyrat (EQ) are three recognised clinical manifestations of penile intra-epithelial neoplasia (carcinoma *in situ*) which are histologically indistinguishable. BP is typically a raised papule on the penile shaft skin in a young male with a history of HPV exposure. BD is a red scaly patch on the penile shaft, and EQ is a shiny erythematous plaque on the mucosal surface of the inner prepuce and/or glans penis. EQ has the highest risk of developing SCC and BP the lowest. Balanitis xerotica obliterans (lichen sclerosus et atrophicus) is a common lesion that is associated with SCC but has no proven direct causal link.

SCC of the penis is classified as classic/usual type, basaloid, verrucous, sarcomatoid or adenosquamous. Growth patterns include superficial spreading, nodular or vertical-phase growth and verrucous growth [1].

### molecular biology

Although several molecular prognostic markers have been evaluated, currently these markers are not useful in clinical practice. SCC antigen is not a sensitive marker of tumour burden and has little prognostic significance for survival in patients with penile cancer treated with surgery [1].

## staging and risk assessment

### tumour-node-metastasis (TNM) classification

Penile cancer should preferably be staged according to the American Joint Committee on Cancer/Union for International Cancer Control (AJCC/UICC) seventh edition TNM classification (see Table 2) [9].

### risk assessment

Patients can be prognostically stratified based on stage and/or grade into three risk groups according to the likelihood of harbouring occult node-positive disease: low-risk group; Tis, TaG1-2 or T1G1, the intermediate-risk group; T1G2 and the high-risk group; T2 or any G3 [10]. Patients with T1G1 penile SCC do not need further nodal assessment after local treatment [1]. In patients with intermediate T1G2 tumours, 13% up to 29% develop LN metastases during follow-up. The 2009 European Association of Urology (EAU) guidelines recommend either DSNB or modified inguinal lymph node dissection (ILND) in clinical N0 patients with T1G2 nodular growth or vascular invasion, T1G3 tumours and in all tumours T2 or higher [C] [10].

At present, the risk for LN metastasis may be predicted by several tumour characteristics other than T and G categories [1]. Specifically, these risk factors include pathological subtypes, invasion of perineural spaces, lymphovascular invasion, tumour depth or thickness, anatomical site, size of the primary tumour, growth pattern, irregular front of invasion, positive margins of resection and urethral invasion. High histological grade, perineural invasion and lymphovascular invasion appear to be the strongest predictors of metastasis of penile cancer [III] [1]. Verrucous carcinoma almost never invades LNs but gives rise to distinct inflammatory nodal enlargement. The presence of central node necrosis and/or an irregular nodal border of the regional LNs are very useful to identify high-risk pathological node-positive penile cancer. Graafland et al. [11] demonstrated an association between these unfavourable factors and poor prognosis, with a sensitivity of 95%, a specificity of 82% and a diagnostic accuracy of 87% [IV]. Nomograms have been

**Table 2.** American Joint Committee on Cancer/Union for International Cancer Control (AJCC/UICC) seventh edition TNM clinical and pathological classification of penile cancer

| | |
|---|---|
| Clinical classification T: primary tumour | |
| TX | Primary tumour cannot be assessed |
| T0 | No evidence of primary tumour |
| Tis | Carcinoma *in situ* |
| Ta | Non-invasive verrucous carcinoma, not associated with destructive invasion |
| T1 | Tumour invades sub-epithelial connective tissue |
| T1a | Without lymphovascular invasion and well or moderately differentiated (T1G1-2) |
| T1b | With lymphovascular invasion or poorly differentiated/undifferentiated (T1G3-4) |
| T2 | Tumour invades corpus spongiosum/corpora cavernosa |
| T3 | Tumour invades urethra |
| T4 | Tumour invades other adjacent structures |
| N: Regional lymph nodes | |
| NX | Regional lymph nodes cannot be assessed |
| N0 | No palpable or visibly enlarged inguinal lymph node |
| N1 | Palpable mobile unilateral inguinal lymph node |
| N2 | Palpable mobile multiple or bilateral inguinal lymph nodes |
| N3 | Fixed inguinal nodal mass or pelvic lymphadenopathy, unilateral or bilateral |
| M: Distant metastasis | |
| M0 | No distant metastasis |
| M1 | Distant metastasis |
| Pathological classification | |
| The pT categories correspond to the T categories. | |
| The pN categories are based upon biopsy or surgical excision. | |
| pN: Regional lymph nodes | |
| pNX | Regional lymph nodes cannot be assessed |
| pN0 | No regional lymph node metastasis |
| pN1 | Intra-nodal metastasis in a single inguinal lymph node |
| pN2 | Metastasis in multiple or bilateral inguinal lymph nodes |
| pN3 | Metastasis in pelvic lymph node(s), unilateral or bilateral or extranodal extension of regional lymph node metastasis |
| pM: Distant metastasis | |
| pM0 | No distant metastasis |
| pM1 | Distant metastasis |
| G: Histological grading | |
| GX | Grade of differentiation cannot be assessed |
| G1 | Well differentiated |
| G2 | Moderately differentiated |
| G3-4 | Poorly differentiated/undifferentiated |

From [12]. Used with the permission of the American Joint Committee on Cancer (AJCC), Chicago, Illinois. The original source for this material is the AJCC Cancer Staging Handbook, Seventh Edition (2010) published by Springer Science and Business Media LLC, www.springer.com.

developed based on clinical and pathologic parameters to predict and identify patients at the risk of nodal metastasis. Recently, Thuret et al. [13] reviewed several nomograms and found that the staging system developed by the AJCC combined with tumour grade was the most simple and most accurate method (80.9%) to predict cancer specific mortality after primary tumour excision for penile cancer. Even the most sensitive nomogram is inaccurate in predicting patients with positive LNs with as many as 75% of patients predicted to be at high risk of LN metastasis being pathologically negative [14].

## treatment

### primary surgery

Until 15 years ago, surgical options to treat invasive penile cancer were limited to minor procedures such as wide local excision and circumcision or more radical amputative procedures loosely divided into partial penectomy and radical penectomy.

The pathological argument for extent of resection was based on the principle that at least a 2cm clear margin from macroscopic disease was required for local control. In many cases, a partial penectomy carried out would leave the patient with a short penile stump, perhaps, but not always, suitable for erect micturition, and with limited sexual function. The psychological morbidity of these procedures was and still remains significant. Radical radiotherapy offered patients a choice of penile preservation albeit with its own treatment complications (see section below). Certainly in the UK, many patients were treated routinely with either external beam or brachytherapy for distal stage T1 and T2 tumours with surgery for salvage recurrences. The evidence that local recurrence did

not adversely influence survival was an important factor in supporting this approach.

Around this time, two important factors encouraged a change in practice. First, surgeons began to question the premise that surgical margins had to be so generous. A margin of <5 mm is adequate for most tumours [III] [15]. The recurrence rate of patients with resection margins of 5 mm or less could still be <5%, and this led to newer penile-preserving techniques being developed. Secondly, and particularly in the UK and the Netherlands, specialist centres treating high volumes of penile cancer patients allowed these techniques to be evaluated. Previously, the main block to progress was the rarity of the disease and small numbers of patients reported in the literature.

In general, we can now group surgical techniques into three broad categories. First, for small volume and superficial penile lesions, circumcision, wide local excision and epithelial ablative techniques are still mainstay treatments. One has to remember that the glanular and preputial mucosa is probably affected as a field change. Local recurrences over time may occur and retreatment is a distinct possibility. Secondly, for glanular and distal penile tumours, it is now possible to preserve much more length, and cosmetic and functional results are far superior to conventional partial penectomy. This balances the argument between the choice of surgery and radiotherapy for such tumours (which in developed countries are the majority of presentations). Thirdly, surgeons are now being more aggressive in extending the preservation techniques, with ongoing studies looking at both less resecting for superficial tumours and more penile reconstruction (phalloplasty) for more advanced tumours suitable only for total penectomy.

The role of salvage surgery after radio/chemotherapy remains an area of controversy. For patients with extensive regional disease in which primary surgery is deemed unlikely to result in a clear margin, attempts at down-staging are appropriate. If the patient responds to treatment, surgical resection can be considered. There is no evidence that surgery in this situation is inherently more complicated than for patients with bulky nodal disease.

There are no direct comparisons between radiotherapy and the newer penile-preserving techniques, and studies with chemotherapy are very limited.

## radiotherapy

*radiotherapy as treatment of the primary tumour.* In order to deliver the radiation dose to the tumour, there are two options: external beam treatment or brachytherapy. By using external megavoltage radiation beams, a relatively homogeneous dose is delivered in the target region. Tissue-equivalent bolus is often required to provide sufficient dose build-up to the surface of the lesion. Using fractionated treatment, schedules can spare normal tissues. A typical radical external beam course consists of one daily fraction of about 2 Gy, five fractions per week during 6–7 weeks to a total dose of 66–70 Gy. Brachytherapy (brachy is from the Greek for short distance) consists of placing sealed radioactive sources very close to or in contact with the tumour. Because the absorbed dose falls off very rapidly with increasing distance from the sources, high doses can be delivered safely to a localised target region over a short time. Compared with external beam treatment, the volume of the area treated to a high dose is smaller, but the dose inhomogeneity within this volume is more pronounced. Penile brachytherapy can be performed under general anesthesia or penile block with systemic sedation. Low dose rate brachytherapy consists of either manually afterloaded 192 Ir or pulse dose rate brachytherapy with automated afterloading with a high-intensity 192 Ir source to deliver hourly pulses. A typical brachytherapy schedule consists of 55–60 Gy given in 4–6 days.

Results of brachytherapy have been reported in about 20 studies. All except two of these studies reported on fewer than 80 patients. The largest study by Rozan et al. [16] reported on 259 patients, of whom 184 had been treated by brachytherapy only and 75 had a combination of external beam treatment and brachytherapy. In the vast majority of the studies, the patients were treated over a period exceeding one or even two or three decades. Treatment parameters such as tumour dose, dose rate, fractionation schedule etc. varied considerably among the patients reported within the individual studies. Also, patient selection criteria were not uniformly applied in most of the reports. Despite this wide variety in treatment parameters and patient characteristics, the outcome of the studies is remarkably concordant [17–19]. Long-term (5–10 years) local control rates vary between 60% and 90% and seem more related to tumour characteristics than treatment parameters. According to the 2013 ABS-GEC-ESTRO consensus statement, the good tumor control rates, acceptable morbidity, and functional organ preservation warrant recommendation of brachytherapy as the initial treatment for invasive T1, T2, and selected T3 penile cancers [20]. Adequate surgical salvage possibilities with a success rate between 70% and 100% are observed and reported penis conservation rate is between 52% and 86%. The most important predictors for successful brachytherapy seem to be tumour size (less or more than 4 cm) and tumour location limited to the glans or the prepuce without corpus cavernosum involvement. For patients meeting these criteria, different studies report local recurrence rates of about 20% after 5–10 years with a secondary control of about 85% of the recurrences by salvage surgery.

External beam treatment as single treatment modality has been used in only a small number of studies, most of these reporting on limited numbers of patients [21]. One exception is a study by Gotsadze et al. [22] analysing results in 155 patients. Reported local control rates for stages I and II range from 65% to 90%. Sarin et al. [23] analysed the impact of various radiation parameters such as total dose, dose per fraction, total treatment time and 'biological equivalent dose' with or without time factor on local failure in 44 patients with T1 tumours. A higher incidence of local failure was observed with total dose <60 Gy, dose per fraction <2 Gy and treatment time exceeding 45 days.

Radiotherapy can induce adverse effects and complications such as teleangiectasia, atrophy and depigmentation of the skin, fibrosis, urethral stenosis and (painful) ulcerations and necrosis. Most serious complications are urethral stenosis and persisting ulceration or necrosis. The reported incidence ranges from 8% to 45% and 0% to 23%, respectively. The reported incidence of penectomy for radiation complications varies from 0% to 5% [19, 23]. Only very few data are available concerning functional and psychosexual outcome of organ preservation by

radiotherapy. Opjordsmoen et al. [24] reported on post-therapy sexuality in 30 men. Patients underwent a semi-structured interview and completed three self-administered questionnaires focusing on psychosocial adjustment to severe illness, mental symptoms and quality of life. A global score of overall sexual function was constructed, consisting of sexual interest, sexual ability, sexual satisfaction, sexual identity, partner relationship and frequency of coitus. In 10 of 12 patients treated with irradiation, the global sexual score was not reduced or was only slightly reduced. Eleven out of 14 patients treated with local surgery, laser beam treatment or partial penectomy had moderate to severe reduction of global sexual score. All four patients who had undergone total penectomy recorded a severely reduced global sexual score. It was remarkable that, in the patients treated by irradiation, physicians evaluated the patients' post-treatment sexuality, especially with regard to the ability to perform coitus, to be more impaired than was evaluated by the patients themselves.

*radiotherapy for the management of regional lymph node metastases*

*elective radiation:* Elective radiation of clinically uninvolved LN regions has proven to be an effective policy in many tumours, especially in SCC. In penile cancer, elective radiotherapy has never been widely used. Arguments against its use have been related to the unproven efficacy, the possibility of complications and the concern that radiation-induced fibrotic changes might hinder reliable follow-up.

*adjuvant postoperative radiation:* The role of adjuvant postoperative radiation is controversial. The incidence of inguinal failure in patients with inguinal LN metastasis treated with lymphadenectomy varies between 25% and 77% [25–27]. Adjuvant radiation to the inguinal lymphatic area has been advocated by some, if histopathological examination of the inguinal specimen revealed more than one metastatic LN and/or extranodal extension. Chen et al. reported that postoperative groin radiation reduced the inguinal recurrence rate from 60% (three recurrences in five patients) to 11% (one recurrence in nine patients) [28]. However, larger series confirming this benefit are lacking.

*chemoradiotherapy:* Although studies in other SCCs of the perineal area, e.g. vulvar and anal cancer, have demonstrated the efficacy of chemoradiation regimes, prospective studies of such strategies are unavailable in penile cancer. A few retrospective studies suggest some benefit of radiotherapy with concurrent cisplatin-based chemotherapy in locally advanced unresectable disease [29, 30].

The precise role of chemoradiation, eventually in combination with targeted therapies, remains an important research question for the near future.

## chemotherapy

The literature on the role of chemotherapy in penile cancer is limited due to the rarity of the disease in Western Europe and the United States with invariably small, prospective and retrospective studies. Results are often obtained over a prolonged period of time reflecting potential selection and referral bias, and pointing to inherent changes in clinical staging and patient management over the period of patient inclusion. There are only phase II and no randomised clinical studies reported; thus, the level of evidence on chemotherapy is no more than grade III and the recommendation C.

Cisplatin has been the cornerstone of combination regimens used. The above mentioned limitations of the various studies, often containing heterogeneous patient populations without stratification for prognostic factors, preclude the drawing of any firm conclusions concerning an optimal first-line or second-line chemotherapy regimen.

The largest prospective study was reported in 1999 and included only 45 patients, who were treated with the combination regimen bleomycin/methotrexate/cisplatin (BMP) [31]. It was advised to omit bleomycin from future studies based on the high incidence of fatalities and severe lung toxic effect. Although the question remains unanswered, it seems likely that a bleomycin-containing cisplatin-based regimen can be safely applied in patients after exclusion of older age, heavy smokers and those with compromised lung function.

Efficacy of anticancer treatment regimens is usually based on results obtained in metastatic cancer patients. Activity/efficacy observed in the neoadjuvant setting before definitive local treatment (often surgery) may fuel enthusiasm and serve as an incentive to apply the same drug or combination of drugs in the metastatic setting. Various regimens have been reported to be effective and to induce partial responses in about 20%–33% of advanced penile cancer patients (prospective studies). In none of the studies were modern Response Evaluation Criteria in Solid Tumors (RECIST) criteria applied to measure clinical responses.

*perioperative chemotherapy.* Cytoreductive neoadjuvant chemotherapy has been applied to allow surgery or radiotherapy to obtain local control, but there are no prospective trials of adjuvant chemotherapy, only small retrospective series. Cisplatin combination chemotherapy regimens are the most widely used and seem to be the most effective [III, C]. Four cycles of neoadjuvant paclitaxel in combination with cisplatin and ifosfamide chemotherapy has been shown to be well tolerated and effective in patients with bulky regional disease (any T, N2 or N3 according to the seventh edition of the AJCC/UICC TNM staging classification system) but who had no evidence of distant metastatic disease [III, C] [32]. An overall (partial and complete) response rate of 50% was achieved with 30% of patients experiencing stable disease and 20% progressive disease. The high response rate allowed consolidation surgery in the majority of patients with a pathologic complete response in 13.6% of patients who completed chemotherapy and underwent surgery. Neoadjuvant chemotherapy followed by consolidation surgery resulted in a meaningful remission in a considerable number of patients, with 30% of patients who remained disease-free at a median follow-up of 36 months (14–59 months) [32]. Also paclitaxel, cisplatin and 5-fluorouracil (5-FU) may provide an attractive regimen and preliminary data of the combination in neoadjuvant setting were reported in 2009 by Pizzocaro et al. [33]. Adjuvant chemotherapy is recommended in pN2-3 patients [C] [34]. Neoadjuvant chemotherapy followed by radical surgery is advisable in unresectable or recurrent LN metastases [C] [32, 35, 36].

**Table 3.** Recommendations for the treatment of penile cancer

| Disease stage | Recommendation | Grade |
|---|---|---|
| Tis or Ta | Penile-preserving techniques, including topical therapy (5% 5-fluorouracil and 5% imiquimod cream) [IV] [41], circumcision and wide local excision [IV] [42], laser therapy using CO2 or Nd:YAG laser [III] [43, 44], partial/total glans resurfacing [III] [45, 46] | C |
| T1G1-2 | Penile-preserving techniques, including wide local excision plus reconstructive surgery with split-thickness skin graft or full-thickness skin graft [III] [47] laser therapy [IV] [48], radiotherapy delivered as EBRT or brachytherapy with interstitial implant [IV] [18, 49, 50] | C |
| T1G3–4, T ≥ 2 | If tumour <50% of the glans and no invasion of the corpora cavernosa: wide local excision or glansectomy [III] [47] | B |
| | Tumours with invasion into corpora cavernosa: partial or total penectomy [III] [51] | B |
| | T1-2, N0 and tumour <4 cm: circumcision followed by brachytherapy alone or EBRT with or without chemotherapy [III] [18, 20, 49, 50] | C |
| | T1-2, N0 and tumour >4 cm: circumcision followed by either EBRT with chemotherapy or brachytherapy in select cases and with post-treatment surveillance [52] | D |
| | For T2 tumours only, radiotherapy with or without concurrent chemotherapy [53] | D |
| | T3-4 or N+: circumcision followed by EBRT with chemotherapy [53] | D |
| Non-palpable lymph nodes | Low- risk (Tis, Ta, T1G1) and intermediate-risk (T1G2) patients without lymphovascular invasion are followed with surveillance [54] | B |
| | DSNB is recommended in patients with non-palpable inguinal lymph nodes T1G2 or greater [1, 53] | B |
| | If positive nodes are found on DSNB, ILND is recommended [III] [55] | B |
| | If DSNB is not available: ILND based on risk factors or nomograms [IV] [10] | C |
| Unilateral or bilateral palpable inguinal nodes | Fine-needle aspiration (FNA) of the LN is standard for these patients (omitting the procedure for high-risk tumours to avoid delay of ILND) [III] [56] | B |
| | A negative FNA result should be confirmed with an excisional biopsy or followed with careful surveillance [1, 53] | C |
| | Positive findings from either procedure warrant an immediate ILND [III] [53, 54] | C |
| | a) If 0-1 nodes are positive → no further treatment | C |
| | b) If ≥2 nodes are positive or when extranodal extension is found (consider adjuvant chemotherapy) → pelvic LND (PLND) (consider postoperative radiotherapy) | |
| | When pelvic LNs (PLNs) are enlarged → systemic chemotherapy or radiotherapy with concurrent chemotherapy + percutaneous biopsy or PET/CT [53] | C |
| Fixed or ulcerated inguinal nodes | Patients with non-fixed nodes can be considered for inguinal node dissection with the option to use a skin flap to cover the defect | C |
| | Patients with fixed nodes should be considered for neoadjuvant chemoradiotherapy [III] [1, 36] | C |
| | Responders receive consolidation surgery (bilateral and deep ILND and ipsilateral PLND if possible) [III] [32] | C |
| | Patients with disease progression or unresectable LN may consider additional systemic chemotherapy, local-field radiotherapy or participation in a clinical trial | C |
| Recurrent disease | For recurrences without invasion of the corpora cavernosa salvage penile-sparing options can be considered [IV] [43–45, 47] | C |
| | Invasion of the corpora cavernosa warrants partial or total penectomy [IV] [22] | B |
| | For local recurrences in the inguinal region, consider systemic chemotherapy, EBRT, surgery or a combination [57] | C |
| Metastatic penile cancer | Treatment options include systemic chemotherapy or radiotherapy or radiotherapy with concurrent chemotherapy [58] | |
| | a) Responders receive consolidation ILND | B |
| | b) For those with no response/ disease progression, consider salvage systemic chemotherapy or radiotherapy for local control and/or best supportive care/ clinical trial | C |

Nd:YAG, neodynium yttrium-aluminium-garnet; EBRT, external beam radiation therapy; ILND, inguinal lymph node dissection; DSNB, dynamic sentinel node biopsy; FNA, fine-needle aspiration; PLND, pelvic lymph node dissection; PET/CT, positron emission tomography/computed tomography.

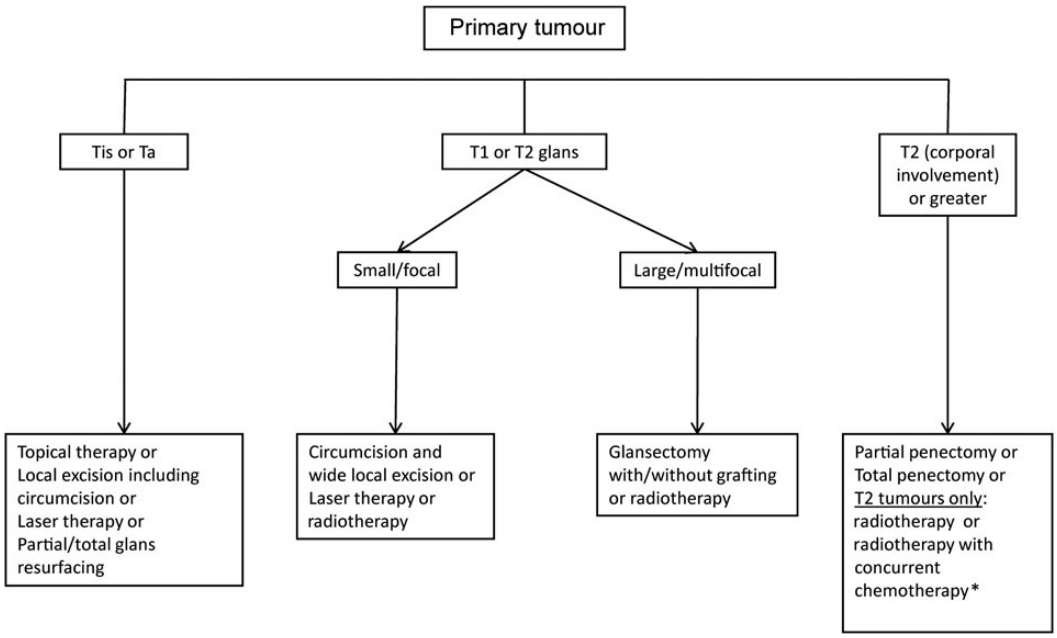


**Figure 1.** Guidelines on treatment strategies for the primary tumour.
* grade of recommendation is D.

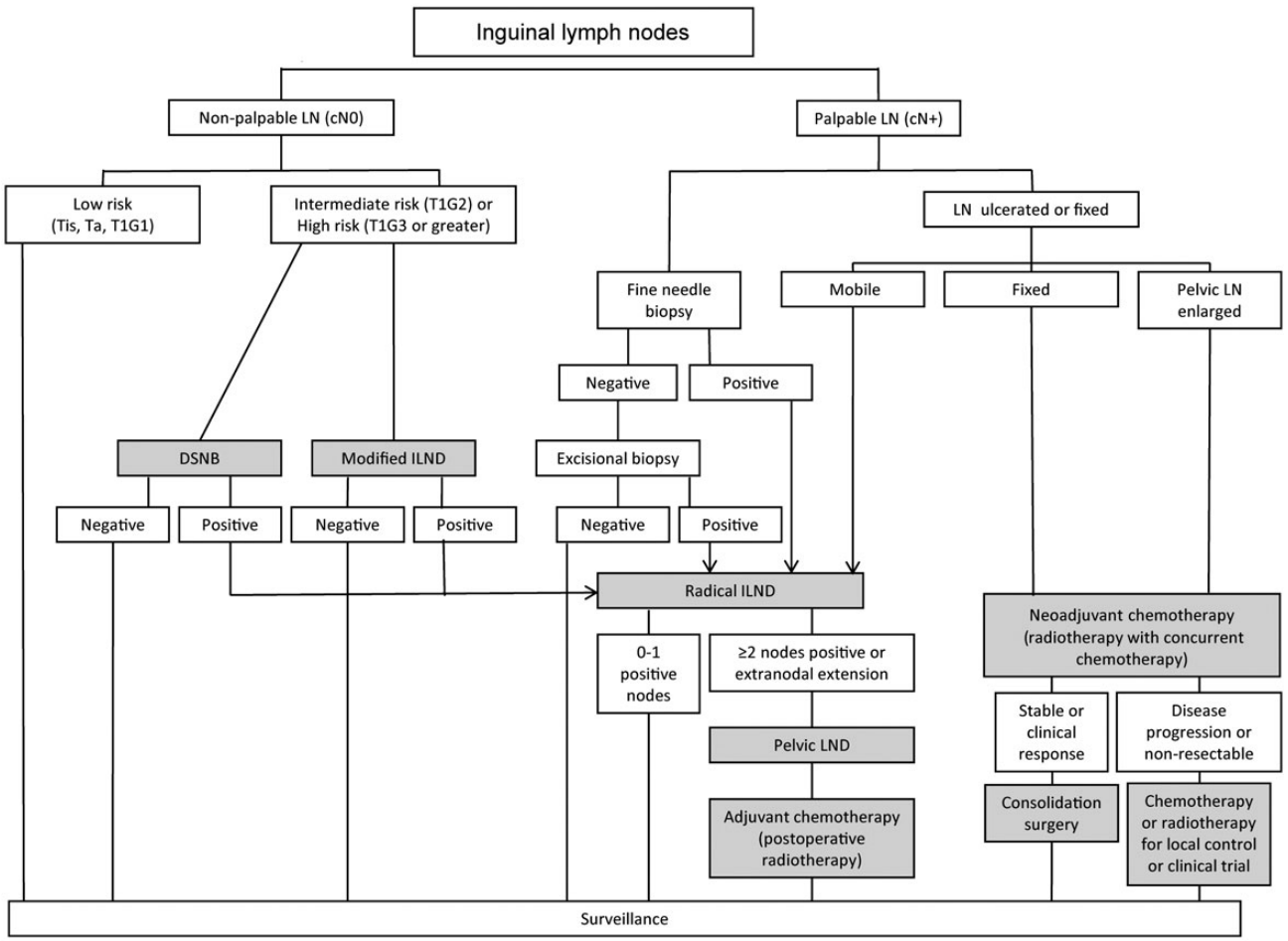


**Figure 2.** Guidelines on treatment strategies for the regional LNs.

**Table 4.** Levels of evidence and grades of recommendation (adapted from the Infectious Diseases Society of America-United States Public Health Service Grading System[a])

| | |
|---|---|
| Levels of evidence | |
| I | Evidence from at least one large randomised, controlled trial of good methodological quality (low potential for bias) or meta-analyses of well-conducted randomised trials without heterogeneity |
| II | Small randomised trials or large randomised trials with a suspicion of bias (lower methodological quality) or meta-analyses of such trials or of trials with demonstrated heterogeneity |
| III | Prospective cohort studies |
| IV | Retrospective cohort studies or case–control studies |
| V | Studies without control group, case reports, experts opinions |
| Grades of recommendation | |
| A | Strong evidence for efficacy with a substantial clinical benefit, strongly recommended |
| B | Strong or moderate evidence for efficacy but with a limited clinical benefit, generally recommended |
| C | Insufficient evidence for efficacy or benefit does not outweigh the risk or the disadvantages (adverse events, costs, …), optional |
| D | Moderate evidence against efficacy or for adverse outcome, generally not recommended |
| E | Strong evidence against efficacy or for adverse outcome, never recommended |

[a]Dykewicz CA. Summary of the guidelines for preventing opportunistic infections among hematopoietic stem cell transplant recipients. Clin Infect Dis 2001; 33: 139–144. By permission of the Infectious Diseases Society of America.

*chemotherapy for advanced disease.* Cisplatin has been used in combination with agents such as 5-FU or irinotecan. Patients were treated in the neoadjuvant setting for T3 or N1-N2 disease with a maximum of four cycles before surgery, or up to eight cycles for T4 or N3 or M1 disease. There were eight clinical responses (30.8%) in 26 eligible patients (two complete and six partial responses) [37]. A sustained palliative response has been observed with combination chemotherapy using cisplatin and gemcitabine for the management of metastatic penile cancer [38]. The chemotherapy combination ifosfamide, paclitaxel and cisplatin may also be a rational regimen in metastatic disease, based on the activity in the neoadjuvant setting [32]. In a retrospective study, cisplatin and 5-FU were used in 25 patients with metastatic penile cancer. Partial responses were observed in 8 patients (32%). The median progression-free survival (PFS) and overall survival (OS) were 20 weeks and 8 months, respectively. The combination was well tolerated. Severe neutropenia was the most important grade 3-4 adverse effect observed, occurring in 20% of patients [39].

Paclitaxel in combination with carboplatin may provide an alternative regimen in patients who are ineligible for cisplatin treatment. The taxane paclitaxel demonstrated efficacy as a single-agent therapy in 25 metastatic patients who were previously treated in the neoadjuvant or adjuvant setting with cisplatin combination chemotherapy regimens, with a partial response rate of 20%. The median PFS was only 11 weeks and the median OS was 23 weeks [III, C] [40].

The phase II or retrospective nature of the studies reported and their small sample size, plus the lack of any randomised clinical trial comparing different regimens, preclude assessment of a superior drug regimen in the setting of patients with distant metastatic disease or bulky regional/locally advanced disease.

Recommendations for treatment strategies for the primary tumour in penile cancer per stage and grade for nodal metastases, recurrent disease and metastatic penile cancer are presented in Table 3.

*primary tumour.* The choice of treatment is influenced by the size and position of the tumour on the glans or in the corpora, the adverse effects of the treatment and the treatment centre's experience. For superficial and glans confined tumours, a penile-preserving strategy is recommended [B] [1]. Guidelines on treatment strategies for the primary tumour are presented in Figure 1.

*regional lymph nodes.* Lymphadenectomy is the standard treatment of patients with inguinal LN metastases [B] [59]. Guidelines on treatment strategies for the regional LNs are presented in Figure 2.

*recurrence.* Local recurrence rate after conservative surgery does not seem to have a negative impact on long-term survival.

*metastatic disease.* The OS of patients with metastatic disease (beyond the pelvic nodes) is 0% at 5 years and <10% at 2 years. Patients who present with metastatic disease have a very poor prognosis and early consideration of palliative care is recommended.

## response evaluation

Penectomy is disfiguring and can have an intense effect on the patient's quality of life, sexual function, self-esteem and general mental health. Therefore, there is an increased trend for penile-preserving strategies, despite the fact that recurrence rates may be higher than those of radical surgical procedures. In the choice of treatment, the patient's preference must be considered. Adverse effects must be weighed against one another to allow correct treatment selection. Also important is the patient's compliance in attending follow-up visits after treatment.

## personalised medicine

In this disease setting, more research is needed to identify molecular markers which could lead to advances in personalised medicine.

## follow-up

The aim of follow-up is to detect early recurrences when they can still be cured. New imaging modalities such as $^{18}$F-FDG PET/CT scanning can improve the detection of early regional and distant metastases. A large retrospective study based on a two-centre analysis of 700 patients with penile cancer showed that 74.1% and 92.2% of all recurrences occurred within the first 2 and 5 years, respectively [60].

### primary tumour

Local recurrence has been reported in 28% of patients during the first 2 years of follow-up after penis-preserving surgery and is significantly higher than the local recurrence rate after penectomy (6%). Following penile-preserving treatment, a follow-up visit every 3 months is advised in the first 2 years and every 6 months in the following 3 years. Patients must continue with regular self-examination and must report any changes even after a 5-year follow-up. After penectomy, the intervals of follow-up visits are 6 months in the first 2 years and 1 year in the following 3 years [C] [60].

### regional recurrences

Most regional recurrences occur within 2 years after ILND or DSNB. For patients subjected to a 'wait-and-see' policy (groins not surgically staged) and patients with positive nodes, meticulous follow-up with ultrasound-guided FNAC biopsy of the groin is advised every 3 months in the first 2 years and every 6 months in the following 3 years [C] [60].

For patients surgically staged for negative nodes, the regional relapse rate is lower and the intervals for follow-up visits (ultrasound-guided FNAC biopsy) are 3 months in the first 2 years and 6 months for years 3–5. The risk of recurrence rates for patients that underwent a 'wait-and-see' policy, for patients staged as pN0 and for patients staged as pN+ were 9%, 2.3% and 19%, respectively [60].

## note

Levels of evidence and grades of recommendation have been applied using the system shown in Table 4. Statements without grading were considered justified standard clinical practice by the experts and the ESMO faculty.

## conflict of interest

Prof. Kataja has reported institutional clinical research support from Sanofi, Bayer Health Care, Orion Pharma and Merck; the arrangements do not involve personal financial support from the companies mentioned. The other authors have declared no potential conflicts of interest.

## references


1. Pizzocaro G, Algaba F, Horenblas S et al. EAU Penile cancer guidelines 2009. Eur Urol 2010; 57: 1002–1012.
2. Ferlay J, Shin HR, Bray F et al. Estimates of worldwide burden of cancer in 2008: Globocan 2008. Int J Cancer 2010; 127: 2893–2917.
3. Lont AP, Horenblas S, Tanis PJ et al. Management of clinically node negative penile carcinoma: improved survival after the introduction of dynamic sentinel node biopsy. J Urol 2003; 170: 783–786.
4. Leijte JA, Hughes B, Graafland NM et al. Two-center evaluation of dynamic sentinel node biopsy for squamous cell carcinoma of the penis. J Clin Oncol 2009; 27: 3325–3329.
5. Sadeghi R, Gholami H, Zakavi SR et al. Accuracy of sentinel lymph node biopsy for inguinal lymph node staging of penile squamous cell carcinoma: systematic review and meta-analysis of the literature. J Urol 2012; 187: 25–31.
6. Graafland NM, Leijte JA, Olmos RA et al. Repeat dynamic sentinel node biopsy in locally recurrent penile carcinoma. BJU Int 2010; 105: 1121–1124.
7. Ornellas AA, Seixas AL, Marota A et al. Surgical treatment of invasive squamous cell carcinoma of the penis: retrospective analysis of 350 cases. J Urol 1994; 151: 1244–1249.
8. Schlenker B, Scher B, Tiling R et al. Detection of inguinal lymph node involvement in penile squamous cell carcinoma by 18f-fluorodeoxyglucose PET/CT: a prospective single-center study. Urol Oncol 2012; 30: 55–59.
9. Sobin L, Gospodariwics M, Wittekind C. TNM Classification of Malignant Tumors. UICC International Union Against Cancer, 7th edition. West Sussex, UK: Willy-Blackwell 2009; 239–242.
10. Solsona E, Algaba F, Horenblas S et al. EAU Guidelines on penile cancer. Eur Urol 2004; 46: 1–8.
11. Graafland NM, Teertstra HJ, Besnard AP et al. Identification of high risk pathological node positive penile carcinoma: value of preoperative computerized tomography imaging. J Urol 2011; 185: 881–887.
12. Edge SB, Byrd DR, Compton CC, eds. AJCC Cancer Staging Handbook, 7th ed. New York, NY: Springer, 2010.
13. Thuret R, Sun M, Abdollah F et al. Tumor grade improves the prognostic ability of American Joint Committee on Cancer stage in patients with penile carcinoma. J Urol 2011; 185: 501–507.
14. Graafland NM, Lam W, Leijte JA et al. Prognostic factors for occult inguinal lymph node involvement in penile carcinoma and assessment of the high-risk EAU subgroup: a two-institution analysis of 342 clinically node-negative patients. Eur Urol 2010; 58: 742–747.
15. Minhas S, Kayes O, Hegarty P et al. What surgical resection margins are required to achieve oncological control in men with primary penile cancer? BJU Int 2005; 96: 1040–1043.
16. Rozan R, Albuisson E, Giraud B et al. Interstitial brachytherapy for penile carcinoma: a multicentric survey (259 patients). Radiother Oncol 1995; 36: 83–93.
17. Kiltie AE, Elwell C, Close HJ et al. Iridium-192 implantation for node-negative carcinoma of the penis: the Cookridge Hospital experience. Clin Oncol (R Coll Radiol) 2000; 12: 25–31.
18. de Crevoisier R, Slimane K, Sanfilippo N et al. Long-term results of brachytherapy for carcinoma of the penis confined to the glans (N- or NX). Int J Radiat Oncol Biol Phys 2009; 74: 1150–1156.
19. Crook J, Grimard L, Tsihlias J et al. Interstitial brachytherapy for penile cancer: an alternative to amputation. J Urol 2002; 167: 506–511.
20. Crook JM, Haie-Meder C, Demanes DJ et al. American Brachytherapy Society-Groupe Europeén de Curiethérapie-European Society of Therapeutic Radiation Oncology (ABS-GEC-ESTRO) consensus statement for penile brachytherapy. Brachytherapy 2013; 12: 191–198.
21. Zouhair A, Coucke PA, Jeanneret W et al. Radiation therapy alone or combined surgery and radiation therapy in squamous-cell carcinoma of the penis? Eur J Cancer 2001; 37: 198–203.
22. Gotsadze D, Matveev B, Zak B, Mamaladze V. Is conservative organ-sparing treatment of penile carcinoma justified? Eur Urol 2000; 38: 306–312.
23. Sarin R, Norman AR, Steel GG, Horwich A. Treatment results and prognostic factors in 101 men treated for squamous carcinoma of the penis. Int J Radiat Oncol Biol Phys 1997; 38: 713–722.
24. Opjordsmoen S, Waehre H, Aass N, Fossa SD. Sexuality in patients treated for penile cancer: patients' experience and doctors' judgement. Br J Urol 1994; 73: 554–560.
25. Horenblas S, van Tinteren H, Delemarre JF et al. Squamous cell carcinoma of the penis. III. treatment of regional lymph nodes. J Urol 1993; 149: 492–497.

26. Culkin DJ, Beer TM. Advanced penile carcinoma. J Urol 2003; 170: 359–365.
27. Ozsahin M, Jichlinski P, Weber DC et al. Treatment of penile carcinoma: to cut or not to cut? Int J Radiat Oncol Biol Phys 2006; 66: 674–679.
28. Chen MF, Chen WC, Wu CT et al. Contemporary management of penile cancer including surgery and adjuvant radiotherapy: an experience in Taiwan. World J Urol 2004; 22: 60–66.
29. Pedrick TJ, Wheeler W, Riemenschneider H. Combined modality therapy for locally advanced penile squamous cell carcinoma. Am J Clin Oncol 1993; 16: 501–505.
30. Eliason M, Bowen G, Bowen A et al. Primary treatment of verrucous carcinoma of the penis with fluorouracil, cis-diamino-dichloro-platinum, and radiation therapy. Arch Dermatol 2009; 145: 950–952.
31. Haas GP, Blumenstein BA, Gagliano RG et al. Cisplatin, methotrexate and bleomycin for the treatment of carcinoma of the penis: a Southwest Oncology Group study. J Urol 1999; 161: 1823–1825.
32. Pagliaro LC, Williams DL, Daliani D et al. Neoadjuvant paclitaxel, ifosfamide, and cisplatin chemotherapy for metastatic penile cancer: a phase II study. J Clin Oncol 2010; 28: 3851–3857.
33. Pizzocaro G, Nicolai N, Milani A. Taxanes in combination with cisplatin and fluorouracil for advanced penile cancer: preliminary results. Eur Urol 2009; 55: 546–551.
34. Pizzocaro G, Piva L, Bandieramonte G, Tana S. Up-to-date management of carcinoma of the penis. Eur Urol 1997; 32: 5–15.
35. Leijte JA, Kerst JM, Bais E et al. Neoadjuvant chemotherapy in advanced penile carcinoma. Eur Urol 2007; 52: 488–494.
36. Bermejo C, Busby JE, Spiess PE et al. Neoadjuvant chemotherapy followed by aggressive surgical consolidation for metastatic penile squamous cell carcinoma. J Urol 2007; 177: 1335–1338.
37. Theodore C, Skoneczna I, Bodrogi I et al. A phase II multicentre study of irinotecan (CPT 11) in combination with cisplatin (CDDP) in metastatic or locally advanced penile carcinoma (EORTC PROTOCOL 30992). Ann Oncol 2008; 19: 1304–1307.
38. Power DG, Galvin DJ, Cuffe S et al. Cisplatin and gemcitabine in the management of metastatic penile cancer. Urol Oncol 2009; 27: 187–190.
39. Di Lorenzo G, Buonerba C, Federico P et al. Cisplatin and 5-fluorouracil in inoperable, stage IV squamous cell carcinoma of the penis. BJU Int 2012; 110: E661–E666.
40. Di Lorenzo G, Federico P, Buonerba C et al. Paclitaxel in pretreated metastatic penile cancer; final results of a phase 2 study. Eur Urol 2011; 60: 1280–1284.
41. Alnajjar HM, Lam W, Bolgeri M et al. Treatment of carcinoma in situ of the glans penis with topical chemotherapy agents. Eur Urol 2012; 62: 923–928.
42. Feldman AS, McDougal WS. Long-term outcome of excisional organ sparing surgery for carcinoma of the penis. J Urol 2011; 186: 1303–1307.
43. Bandieramonte G, Colecchia M, Mariani L et al. Peniscopically controlled CO2 laser excision for conservative treatment of in situ and T1 penile carcinoma: report on 224 patients. Eur Urol 2008; 54: 875–882.
44. Windahl T, Andersson SO. Combined laser treatment for penile carcinoma: results after long-term followup. J Urol 2003; 169: 2118–2121.
45. Hadway P, Corbishley CM, Watkin NA. Total glans resurfacing for premalignant lesions of the penis: initial outcome data. BJU Int 2006; 98: 532–536.
46. Shabbir M, Muneer A, Kalsi J et al. Glans resurfacing for the treatment of carcinoma in situ of the penis: surgical technique and outcomes. Eur Urol 2011; 59: 142–147.
47. Smith Y, Hadway P, Biedrzycki O et al. Reconstructive surgery for invasive squamous carcinoma of the glans penis. Eur Urol 2007; 52: 1179–1185.
48. Schlenker B, Tilki D, Seitz M et al. Organ-preserving neodymium-yttrium-aluminium-garnet laser therapy for penile carcinoma: a long-term follow-up. BJU Int 2010; 106: 786–790.
49. Azrif M, Logue JP, Swindell R et al. External-beam radiotherapy in T1–2 N0 penile carcinoma. Clin Oncol (R Coll Radiol) 2006; 18: 320–325.
50. Crook JM, Girmard L, Esche B, Pond G. Penile brachytherapy: results for 60 patients. Brachytherapy 2007; 6: 82.
51. Lont AP, Gallee MP, Meinhardt W et al. Penis conserving treatment for T1 and T2 penile carcinoma: clinical implications of a local recurrence. J Urol 2006; 176: 575–580; discussion 580.
52. Crook J, Jezioranski J, Cygler JE. Penile brachytherapy: technical aspects and postimplant issues. Brachytherapy 2010; 9: 151–158.
53. National Comprehensive Cancer Network (NCCN). NCCN Clinical Practice Guidelines in Oncology: Penile Cancer, version 1, 2013. http://www.nccn.org/professionals/physician_gls/pdf/penile.pdf. (15 July 2013, date last accessed).
54. Ornellas AA, Kinchin EW, Nóbrega BL et al. Surgical treatment of invasive squamous cell carcinoma of the penis: Brazilian National Cancer Institute long-term experience. J Surg Oncol 2008; 97: 487–495.
55. Leijte JA, Kroon BK, Valdés Olmos RA et al. Reliability and safety of current dynamic sentinel node biopsy for penile carcinoma. Eur Urol 2007; 52: 170–177.
56. Saisorn I, Lawrentschuk N, Leewansangtong S, Bolton DM. Fine-needle aspiration cytology predicts inguinal lymph node metastasis without antibiotic pretreatment in penile carcinoma. BJU Int 2006; 97: 1225–1228.
57. Graafland NM, Moonen LM, van Boven HH et al. Inguinal recurrence following therapeutic lymphadenectomy for node positive penile carcinoma: outcome and implications for management. J Urol 2011; 185: 888–893.
58. Pettaway CA, Pagliaro L, Theodore C, Haas G. Treatment of visceral, unresectable, or bulky/unresectable regional metastases of penile cancer. Urology 2010; 76 (Suppl. 1): S58–S65.
59. Horenblas S. Lymphadenectomy in penile cancer. Urol Clin North Am 2011; 38: 459–469, vi–vii.
60. Leijte JA, Kirrander P, Antonini N et al. Recurrence patterns of squamous cell carcinoma of the penis: recommendations for follow-up based on a two- centre analysis of 700 patients. Eur Urol 2008; 54: 161–168.