

NCCN Clinical Practice Guidelines in Oncology (NCCN Guidelines®)

Dermatofibrosarcoma Protuberans

Version 1.2018 — September 18, 2017

NCCN.org

Continue



National
Comprehensive
Cancer
Network®

NCCN Guidelines Version 1.2018 Panel Members

Dermatofibrosarcoma Protuberans

[NCCN Guidelines Index](#)
[Table of Contents](#)
[Discussion](#)

*Christopher K. Bichakjian, MD/Chair ☐
University of Michigan
Comprehensive Cancer Center

Kris Fisher, MD ☐ ≠
St. Jude Children's Research Hospital/
University of Tennessee Health Science Center

Paul Nghiem, MD, PhD ☐
Fred Hutchinson Cancer Research
Center/Seattle Cancer Care Alliance

Thomas Olencki, DO/Vice-Chair †
The Ohio State University Comprehensive
Cancer Center - James Cancer Hospital
and Solove Research Institute

Brian Gastman, MD ¶
Case Comprehensive Cancer Center/
University Hospitals Seidman Cancer Center and
Cleveland Clinic Taussig Cancer Institute

Igor Puzanov, MD ‡
Roswell Park Cancer Institute

Sumaira Z. Aasi, MD ☐
Stanford Cancer Institute

Karthik Ghosh, MD ¶
Mayo Clinic Cancer Center

Chrysalynne D. Schmults, MD ☐ ¶
Dana-Farber/Brigham and Women's
Cancer Center | Massachusetts General
Hospital Cancer Center

Murad Alam, MD ☐ ¶ ζ
Robert H. Lurie Comprehensive Cancer
Center of Northwestern University

Roy C. Grekin, MD ☐ ¶
UCSF Helen Diller Family
Comprehensive Cancer Center

Ashok R. Shaha, MD ¶ ζ
Memorial Sloan Kettering Cancer Center

James S. Andersen, MD ¶ ¶
City of Hope
Comprehensive Cancer Center

Kenneth Grossman, MD, PhD †
Huntsman Cancer Institute at
the University of Utah

Valencia Thomas, MD ☐
The University of Texas
MD Anderson Cancer Center

Rachel Blitzblau, MD, PhD §
Duke Cancer Center

Alan L. Ho, MD, PhD †
Memorial Sloan Kettering Cancer Center

Yaohui G. Xu, MD, PhD ☐
University of Wisconsin
Carbone Cancer Center

Glen M. Bowen, MD ☐
Huntsman Cancer Institute
at the University of Utah

Karl D. Lewis, MD †
University of Colorado Cancer Center

John A. Zic, MD ☐
Vanderbilt-Ingram Cancer Center

Carlo M. Contreras, MD ¶
University of Alabama at Birmingham
Comprehensive Cancer Center

Manisha Loss, MD ☐
Sidney Kimmel Comprehensive
Cancer Center at Johns Hopkins

Gregory A. Daniels, MD, PhD † ≠ ¶
UC San Diego Moores Cancer Center

Daniel D. Lydiatt, DDS, MD ¶
Fred & Pamela Buffett Cancer Center

Roy Decker, MD, PhD §
Yale Cancer Center/
Smilow Cancer Hospital

Jane Messina, MD ≠
Moffitt Cancer Center

Jeffrey M. Farma, MD ¶
Fox Chase Cancer Center

Kishwer S. Nehal, MD ☐ ¶
Memorial Sloan Kettering Cancer Center

☐ Dermatology
☐ Diagnostic/Interventional radiology
¶ Surgery/Surgical oncology
ζ Otolaryngology
≠ Pathology/Dermatopathology
† Medical oncology
¶ Internal medicine
§ Radiotherapy/Radiation oncology
¶ Reconstructive surgery
‡ Hematology/Hematology oncology
* Discussion Section Writing Committee

NCCN
Anita Engh, PhD
Karin G. Hoffmann, RN, CCM

Continue

[NCCN Guidelines Panel Disclosures](#)



National
Comprehensive
Cancer
Network®

NCCN Guidelines Version 1.2018 Table of Contents

Dermatofibrosarcoma Protuberans

[NCCN Guidelines Index](#)
[Table of Contents](#)
[Discussion](#)

[NCCN Dermatofibrosarcoma Protuberans Panel Members](#)
[Summary of the Guidelines Updates](#)

Dermatofibrosarcoma Protuberans

[Clinical Presentation and Workup \(DFSP-1\)](#)

[Treatment and Follow-up \(DFSP-2\)](#)

[Principles of Pathology \(DFSP-A\)](#)

[Principles of Excision \(DFSP-B\)](#)

Clinical Trials: NCCN believes that the best management for any patient with cancer is in a clinical trial. Participation in clinical trials is especially encouraged.

To find clinical trials online at NCCN Member Institutions, [click here:](#)
nccn.org/clinical_trials/physician.html.

NCCN Categories of Evidence and Consensus: All recommendations are category 2A unless otherwise indicated.

See [NCCN Categories of Evidence and Consensus](#).

The NCCN Guidelines® are a statement of evidence and consensus of the authors regarding their views of currently accepted approaches to treatment. Any clinician seeking to apply or consult the NCCN Guidelines is expected to use independent medical judgment in the context of individual clinical circumstances to determine any patient's care or treatment. The National Comprehensive Cancer Network® (NCCN®) makes no representations or warranties of any kind regarding their content, use or application and disclaims any responsibility for their application or use in any way. The NCCN Guidelines are copyrighted by National Comprehensive Cancer Network®. All rights reserved. The NCCN Guidelines and the illustrations herein may not be reproduced in any form without the express written permission of NCCN. ©2017.



NCCN Guidelines Version 1.2018 Updates

Dermatofibrosarcoma Protuberans

Updates in Version 1.2018 of the NCCN Guidelines for Dermatofibrosarcoma Protuberans from Version 1.2017 include:

Dermatofibrosarcoma Protuberans

DFSP-2

• Adjuvant Treatment

- ▶ For positive surgical margins pathway statement was amended: “RT (preferred) ~~or Consider imatinib mesylate and Multidisciplinary consultation~~”

• Therapy For Recurrence/Metastasis

▶ Recurrence pathway

- ◇ Statement was amended: “Re-resection if feasible (preferred) ~~and consider adjuvant RT...~~”
- ◇ Footnote “h” was added: “For negative margins, RT is not recommended. RT can be considered for treatment of positive margins if not given previously and further resection is not feasible.”

▶ Metastasis pathway

- ◇ Statement was removed: “Consider clinical trial, imatinib mesylate, chemotherapy, RT, or resection as feasible, given the specific clinical circumstances”
- ◇ Footnote “j” was added to “Multidisciplinary Consultation”: “See NCCN Guidelines for STAGE IV Soft Tissue Sarcoma (EXTSARC-5)”
- ◇ Footnote was removed: “AIM (doxorubicin/ifosfamide/mesna) regimen or single-agent therapy with doxorubicin, ifosfamide, epirubicin, gemcitabine, dacarbazine, liposomal doxorubicin, temozolomide, vinorelbine, or pazopanib may be considered.”

- Footnote “f” for RT was amended: “50–60 Gy for ~~close-to-positive indeterminate~~ or positive margins, and up to 66 Gy for gross tumor (2 Gy fractions per day). Fields to extend widely beyond surgical margin (eg, 3–5 cm) when clinically feasible.”

DFSP-B Principles of Excision

• Under Varied Approaches

- ▶ Footnote “1” for Mohs micrographic surgery was amended: “Mohs micrographic surgery is used primarily in DFSP to ensure complete removal and clear margins, and secondarily for its tissue-sparing capabilities. *When Mohs micrographic surgery with margin assessment is being performed and the preoperative biopsy is considered insufficient for providing all the staging information required to properly treat the tumor, consider submission of the central specimen for permanent vertical sections.*”
- ▶ Footnote “2” for CCPDMA was amended: “~~Usually~~ Should be performed as a meticulous, comprehensive en face permanent section examination of all surgical margins.
- ▶ A bullet was removed: “Modified Mohs = Mohs micrographic surgery with additional final margin for permanent section assessment.”




NCCN Guidelines Version 1.2018

Dermatofibrosarcoma Protuberans


CLINICAL PRESENTATION

WORKUP

Suspicious lesion



- H&P
- Complete skin exam
- Biopsy^{a,b}
 - ▶ Hematoxylin and eosin (H&E)
 - ▶ Immunopanel (eg, CD34, factor XIIIa)
 - ▶ Note and report evidence of fibrosarcomatous change or other high-risk features^c
- Consider MRI with contrast for treatment planning if extensive extracutaneous extension is suspected



[See Treatment \(DFSP-2\)](#)

^aThis tumor is frequently misdiagnosed due to inadequate tissue sampling/superficial biopsy. Punch or incisional biopsy, preferably of deeper subcutaneous layer, is strongly recommended for sufficient tissue sampling and accurate pathologic assessment. If biopsy is indeterminate or clinical suspicion remains, rebiopsy is recommended. Wide undermining is discouraged due to the difficulty of interpreting subsequent re-excisions pathologically and of preventing possible tumor seeding.

^b[Principles of Pathology \(DFSP-A\)](#).

^cIf fibrosarcomatous changes/malignant transformations are noted, see the [NCCN Guidelines for Soft Tissue Sarcoma](#). Multidisciplinary consultation is recommended for other high-risk features.

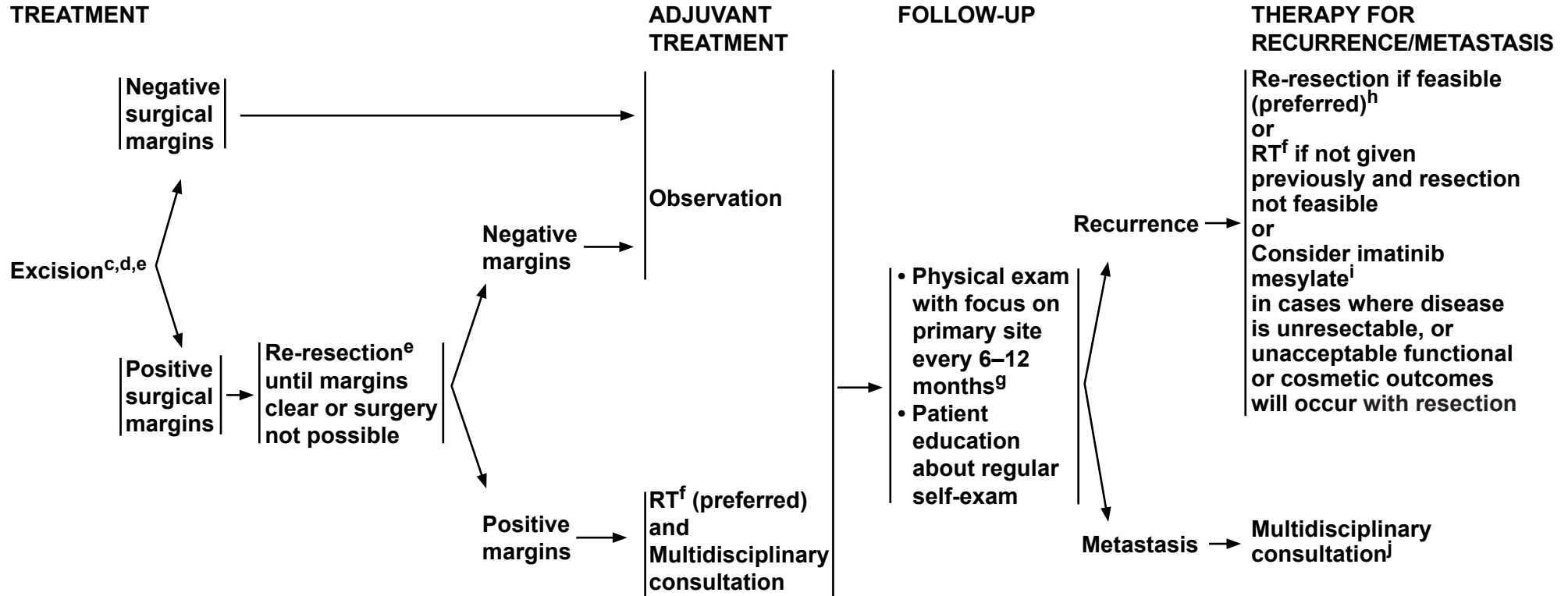
Note: All recommendations are category 2A unless otherwise indicated.

Clinical Trials: NCCN believes that the best management of any patient with cancer is in a clinical trial. Participation in clinical trials is especially encouraged.



NCCN Guidelines Version 1.2018

Dermatofibrosarcoma Protuberans



^cIf fibrosarcomatous changes/malignant transformations are noted, see the [NCCN Guidelines for Soft Tissue Sarcoma](#). Multidisciplinary consultation is recommended for other high-risk features.

^dThe surgical approach to DFSP must be meticulously planned. Size and location of the tumor and cosmetic issues will dictate the most appropriate surgical procedure. [See Principles of Excision \(DFSP-B\)](#).

^eWide undermining is discouraged due to the difficulty of interpreting subsequent re-excisions pathologically and of preventing possible tumor seeding if margins are not histologically clear.

^f50–60 Gy for indeterminate or positive margins, and up to 66 Gy for gross tumor (2 Gy fractions per day). Fields to extend widely beyond surgical margin (eg, 3–5 cm) when clinically feasible.

^gMRI with contrast may be helpful to detect early recurrence in patients with high-risk lesions or who have had more extensive reconstruction.

^hFor negative margins, RT is not recommended. RT can be considered for treatment of positive margins if not given previously and further resection is not feasible.

ⁱTumors lacking the t(17;22) translocation may not respond to imatinib. Molecular analysis of a tumor using cytogenetics may be useful prior to the institution of imatinib therapy.

^j[See NCCN Guidelines for STAGE IV Soft Tissue Sarcoma \(EXTSARC-5\)](#).

Note: All recommendations are category 2A unless otherwise indicated.

Clinical Trials: NCCN believes that the best management of any patient with cancer is in a clinical trial. Participation in clinical trials is especially encouraged.



PRINCIPLES OF PATHOLOGY¹

- **The spindled cells arranged in a storiform or fascicular pattern are typically bland with minimal cytologic atypia.**
- **Immunohistochemistry for CD34 is mostly positive, and factor XIIIa negative.**
- **Fibrosarcomatous transformation (FS-DFSP) is reflected by a higher degree of cellularity, cytologic atypia, mitotic activity (>5/10 HPF), and negative CD34 immunostaining.²**
- **Consider additional immunostaining with nestin, apolipoprotein D, and cathepsin K for equivocal lesions, or FISH (fluorescence in situ hybridization) or PCR for translocation of collagen type I alpha 1 (COL1A1; on 17q22) with platelet-derived growth factor Beta (PDGFβ; on 22q13) to form the oncogenic chimeric fusion gene t(17;22)(q22;q13).**
- **Margin control during excision may require H&E sections supplemented by CD34 immunohistochemistry.**

HPF = High-power fields

¹Currently, no AJCC or CAP synoptic reporting is defined.

²FS-DPSF should be noted when present as it is associated with a poor prognosis.

Note: All recommendations are category 2A unless otherwise indicated.

Clinical Trials: NCCN believes that the best management of any patient with cancer is in a clinical trial. Participation in clinical trials is especially encouraged.

PRINCIPLES OF EXCISION

Goal:

- **Every effort should be made to achieve clear surgical margins. Some form of complete histologic surgical margin examination is recommended, whenever possible. Tumor characteristics include long, irregular, subclinical extensions. Specimens from debulking/Mohs excisions should be examined to identify fibrosarcomatous transformation (FS-DFSP) if present.**

[See the NCCN Guidelines for Soft Tissue Sarcoma for Principles of Sarcoma Surgery \(SARC-C\)](#)

Varied Approaches:

- **Mohs micrographic surgery¹**
- **CCPDMA = Complete circumferential and peripheral deep margin assessment.²**
- **Wide excision with at least 2-cm margins to investing fascia of muscle or pericranium with clear pathologic margins, when clinically feasible.**

Reconstruction:

- **It is recommended that any reconstruction involving extensive undermining or tissue movement be avoided or delayed until negative histologic margins are verified to prevent possible tumor seeding if margins are not histologically clear.**
- **If there is concern that the surgical margins are not completely clear, consider split-thickness skin grafting (STSG) to monitor for recurrence.**

¹Mohs micrographic surgery is used primarily in DFSP to ensure complete removal and clear margins, and secondarily for its tissue-sparing capabilities. When Mohs micrographic surgery with margin assessment is being performed and the preoperative biopsy is considered insufficient for providing all the staging information required to properly treat the tumor, consider submission of the central specimen for permanent vertical sections.

²Should be performed as a meticulous, comprehensive en face permanent section examination of all surgical margins.

Note: All recommendations are category 2A unless otherwise indicated.

Clinical Trials: NCCN believes that the best management of any patient with cancer is in a clinical trial. Participation in clinical trials is especially encouraged.



NCCN Guidelines Version 1.2018 Dermatofibrosarcoma Protuberans

Discussion

This discussion is being updated to correspond with the newly updated algorithm. Last updated 12/16/14

NCCN Categories of Evidence and Consensus

Category 1: Based upon high-level evidence, there is uniform NCCN consensus that the intervention is appropriate.

Category 2A: Based upon lower-level evidence, there is uniform NCCN consensus that the intervention is appropriate.

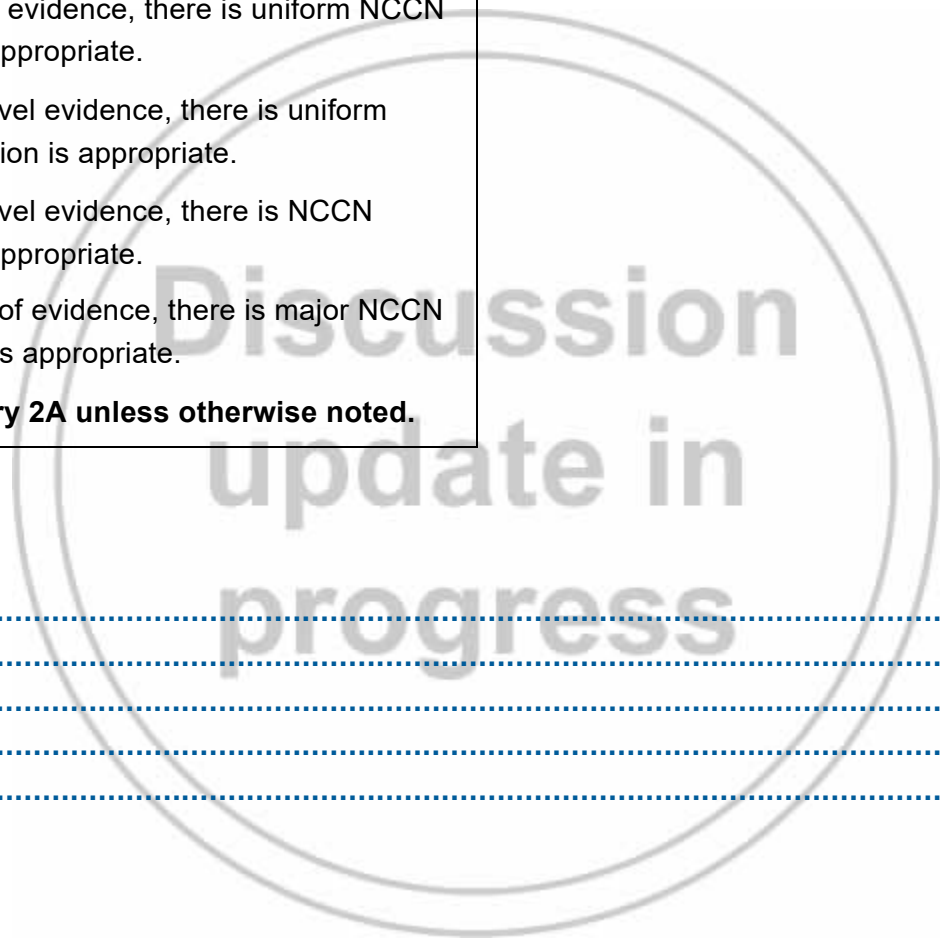
Category 2B: Based upon lower-level evidence, there is NCCN consensus that the intervention is appropriate.

Category 3: Based upon any level of evidence, there is major NCCN disagreement that the intervention is appropriate.

All recommendations are category 2A unless otherwise noted.

Table of Contents

Overview	MS-2
Diagnosis	MS-2
Treatment	MS-3
Follow-up	MS-4
References	MS-5



Overview

Dermatofibrosarcoma protuberans (DFSP) is an uncommon, low-grade sarcoma of fibroblast origin with an incidence rate of 4.2 to 4.5 cases per million persons per year in the United States.^{1,2} It rarely metastasizes. However, initial misdiagnosis, prolonged time to accurate diagnosis, and large tumor size at the time of diagnosis are common. Three-dimensional reconstruction of DFSP³ has revealed tumors with highly irregular shapes and frequent finger-like extensions.⁴ As a result, incomplete removal and subsequent recurrence are common. The local recurrence rate for DFSP in studies ranges from 10% to 60%, whereas the rate of development of regional or distant metastatic disease is only 1% and 4% to 5%, respectively.⁵

The NCCN Non-Melanoma Skin Cancer Panel has developed these guidelines outlining the treatment of DFSP to supplement their other guidelines ([NCCN Guidelines for Basal Cell and Squamous Cell Skin Cancers](#) and [NCCN Guidelines for Merkel Cell Carcinoma](#)). This guideline also received expert input from the NCCN Soft Tissue Sarcoma Panel during its initial development.

Diagnosis

As with all solid tumors, clinical suspicion is confirmed by biopsy. A Principles of Pathology section has been added to the algorithm. Histologically, DFSP typically presents as a storiform or fascicular proliferation of bland spindled cells that extends from the dermis into the subcutis.^{6,7} Virtually all cases are CD34-positive and factor XIIIa-negative with rare exceptions.^{8,9} Currently, no synoptic reporting is recommended.

In most cases, examination of hematoxylin and eosin-stained specimens by light microscopy results in an unequivocal diagnosis.

However, differentiation of DFSP from dermatofibroma can be difficult, at times. In such instances, immunostaining with CD34, factor XIIIa, nestin, apolipoprotein D, and cathepsin K may be useful.¹⁰⁻¹² The panel recommends that appropriate and confirmatory immunostaining be performed in all cases of suspected DFSP. Finally, it is unclear whether the histologic features of a high mitotic rate or evidence of fibrosarcomatous change (typically in more than 5% of the surgical specimen) have prognostic significance in DFSP. Studies in the biomedical literature both support^{13,14} and refute¹⁵ this notion. Thus, the panel requested that fibrosarcomatous change and other high-risk features (such as deep lesions and high grade) be noted in all pathology reports assessing this tumor. Clinicians should consult the [NCCN Guidelines for Soft Tissue Sarcoma](#) when fibrosarcomatous transformations are present.

As the superficial aspect of a DFSP may appear similar to other benign lesions, panelists strongly recommend a deep subcutaneous punch biopsy or incisional biopsy. This will enhance pathologic assessment to avoid misdiagnosis. When the clinician's suspicion for DFSP is high, but the initial biopsy does not support the diagnosis, re-biopsy is recommended and may reveal tumor presence. Wide undermining of the skin is discouraged because it may potentially result in tumor-seeding. It can also interfere with pathologic examination of re-excisions.

Because metastatic disease is rare, an extensive workup is not routinely indicated unless suggestive aspects in the history and physical (H&P) examination or adverse prognostic histologic features are present. Patients with high-risk features may benefit from multidisciplinary consultation as it may optimize clinical and reconstructive outcomes.¹⁶

Treatment

Initial treatment of DFSP is surgical. Because of its proclivity for irregular and frequently deep subclinical extensions, every effort should be made to completely remove this tumor at the time of initial therapy. If initial surgery yields positive margins, re-resection is recommended whenever possible, with the goal of achieving clear margins. The surgical approach to DFSP must be meticulously planned. Size and location of the tumor as well as cosmetic issues will dictate the most appropriate surgical procedure. As noted in the algorithm, some form of complete histologic assessment of all surgical margins before reconstruction is preferred. See [NCCN Guidelines for Soft Tissue Sarcoma](#) for principles of sarcoma surgery. Mohs or modified Mohs surgery,^{3,4,17-24} and traditional wide excision,²⁵ typically with 2- to 4-cm margins to investing fascia that are subsequently verified to be clear by traditional pathologic examination, are all methods to achieve complete histologic assessment.^{18,26,27} A large retrospective series of 204 patients with DFSP showed a very low local recurrence rate (1%) using wide excision with a standardized surgical approach, underscoring the importance of meticulous pathologic margin evaluation with any surgical technique.²⁷ Two systematic reviews found a lower rate of recurrence with Mohs surgery compared to wide local excision.^{28,29} In a retrospective review of 48 patients, positive margins were more frequent with wide excision than with Mohs, but the local recurrence rates were statistically similar.³⁰ It is recommended that any reconstruction involving extensive undermining be avoided. Tissue movement, if necessary, should be delayed until negative histologic margins are verified to prevent possible tumor seeding if margins are not histologically clear. If there is concern that the surgical margins are not completely clear, split-thickness skin grafting should be considered to monitor for recurrence. A retrospective study of 19 patients suggests that coordinated efforts of a team of Mohs surgeon, surgical oncologist,

dermatopathologist, and plastic surgeon can enhance oncologic and reconstructive outcomes.¹⁶

DFSP is characterized by a translocation between chromosomes 17 and 22 [t(17;22)(q22;q13)] resulting in the overexpression of platelet-derived growth factor receptor β (PDGFRB).³¹⁻³³ These findings suggest that targeting PDGF receptors may lead to the development of new therapeutic options for DFSP. In published results, imatinib mesylate, a protein tyrosine kinase inhibitor, has shown clinical activity against localized and metastatic DFSP tumors containing t(17;22)(q22;q13).³⁴⁻³⁸ Imatinib mesylate has been approved by the FDA for the treatment of unresectable, recurrent, and/or metastatic DFSP in adult patients.³⁹ It may be considered in cases where the disease is unresectable following multiple resections, or if unacceptable functional or cosmetic outcomes would occur with further resection. Because tumors lacking the t(17;22) translocation may not respond to imatinib, molecular analysis of a tumor using cytogenetics may be useful prior to the institution of imatinib therapy.

Radiation has occasionally been used as a primary therapeutic modality for DFSP,⁴⁰ but it is more commonly used as adjuvant therapy after surgery.⁴¹⁻⁴⁵ In a single-institution retrospective review of 53 patients, surgery and radiation achieved an excellent local control rate and disease-free survival of 93% at 10 years.⁴⁶ About half of the patients in the study presented initially with recurrent disease. Another small patient series reported that 86% of patients treated with radiation (mostly after surgery) remained disease-free at a median follow-up of 10.5 years.⁴⁷ Postoperative radiation therapy is a preferred option for positive surgical margins if further resection is not feasible. If a negative margin is achieved, no adjuvant treatment is necessary.

Recurrent tumors should be resected whenever possible. Adjuvant radiation may be considered after surgery. For patients who are not surgical candidates, radiation therapy alone is an option if not given previously. Imatinib mesylate should be considered if this is not possible, or if additional resection would lead to unacceptable functional or cosmetic outcomes.

In the rare event of metastatic disease, multidisciplinary consultation is recommended to coordinate treatment. Clinical trials, imatinib mesylate, chemotherapy, radiation therapy, or re-resection as feasible under specific clinical circumstances should be considered. Combined or single-agent chemotherapy commonly used for sarcoma may be considered for DFSP. These include AIM (doxorubicin/ifosfamide/mesna), doxorubicin, ifosfamide, epirubicin, gemcitabine, dacarbazine, liposomal doxorubicin, temozolomide, vinorelbine, or pazopanib (see [NCCN Guidelines for Soft Tissue Sarcoma](#)).

Several clinical trials are underway for the treatment of DFSP with imatinib. To access current clinical trials, go to www.clinicaltrials.gov.

Follow-up

Finally, given the historically high local recurrence rates for DFSP, ongoing clinical follow-up with focus on the primary site every 6 to 12 months is indicated, with re-biopsy of any suspicious regions. Although metastatic disease is rare, a guided H&P should be performed as well. For patients with high-risk features or who have undergone extensive surgery, additional imaging studies may be useful in detecting recurrence.

References

1. Criscione VD, Weinstock MA. Descriptive epidemiology of dermatofibrosarcoma protuberans in the United States, 1973 to 2002. *J Am Acad Dermatol* 2007;56:968-973. Available at: <http://www.ncbi.nlm.nih.gov/pubmed/17141362>.
2. Rouhani P, Fletcher CD, Devesa SS, Toro JR. Cutaneous soft tissue sarcoma incidence patterns in the U.S. : an analysis of 12,114 cases. *Cancer* 2008;113:616-627. Available at: <http://www.ncbi.nlm.nih.gov/pubmed/18618615>.
3. Haycox CL, Odland PB, Olbricht SM, Casey B. Dermatofibrosarcoma protuberans (DFSP): growth characteristics based on tumor modeling and a review of cases treated with Mohs micrographic surgery. *Ann Plast Surg* 1997;38:246-251. Available at: <http://www.ncbi.nlm.nih.gov/pubmed/9088462>.
4. Ratner D, Thomas CO, Johnson TM, et al. Mohs micrographic surgery for the treatment of dermatofibrosarcoma protuberans. Results of a multiinstitutional series with an analysis of the extent of microscopic spread. *J Am Acad Dermatol* 1997;37:600-613. Available at: <http://www.ncbi.nlm.nih.gov/pubmed/9344201>.
5. Vidimos AT, Helm TN, Papay FA. Dermatofibrosarcoma protuberans. In: *Cutaneous Oncology: Pathophysiology, Diagnosis, and Management*. Malden, MA: Blackwell Scientific; 1998.
6. Mentzel T, Pedeutour F, Lazar A, Coindre JM, eds. Dermatofibrosarcoma Protuberans in WHO Classification of Tumors of Soft Tissue and Bone. In: Fletcher CD, Bridge JA, Hogendoorn PCW, Mertens F, eds (ed 4): IARC Press; 2013.
7. Connective Tissue Tumors. In: Calonje E, Brenn T, Lazar A, McKee PH, eds. *McKee's Pathology of the Skin with Clinical Correlations* (ed 4): Elsevier Saunders; 2012:1630-1635.
8. Abenoza P, Lillemoe T. CD34 and factor XIIIa in the differential diagnosis of dermatofibroma and dermatofibrosarcoma protuberans. *Am J Dermatopathol* 1993;15:429-434. Available at: <http://www.ncbi.nlm.nih.gov/pubmed/7694515>.
9. Aiba S, Tabata N, Ishii H, et al. Dermatofibrosarcoma protuberans is a unique fibrohistiocytic tumour expressing CD34. *Br J Dermatol* 1992;127:79-84. Available at: <http://www.ncbi.nlm.nih.gov/pubmed/1382538>.
10. Sellheyer K, Nelson P, Krahl D. Dermatofibrosarcoma protuberans: a tumour of nestin-positive cutaneous mesenchymal stem cells? *Br J Dermatol* 2009;161:1317-1322. Available at: <http://www.ncbi.nlm.nih.gov/pubmed/19659472>.
11. Lisovsky M, Hoang MP, Dresser KA, et al. Apolipoprotein D in CD34-positive and CD34-negative cutaneous neoplasms: a useful marker in differentiating superficial acral fibromyxoma from dermatofibrosarcoma protuberans. *Mod Pathol* 2008;21:31-38. Available at: <http://www.ncbi.nlm.nih.gov/pubmed/17885669>.
12. Yan X, Takahara M, Xie L, et al. Cathepsin K expression: a useful marker for the differential diagnosis of dermatofibroma and dermatofibrosarcoma protuberans. *Histopathology* 2010;57:486-488. Available at: <http://www.ncbi.nlm.nih.gov/pubmed/20727023>.
13. Mentzel T, Beham A, Katenkamp D, et al. Fibrosarcomatous ("high-grade") dermatofibrosarcoma protuberans: clinicopathologic and immunohistochemical study of a series of 41 cases with emphasis on prognostic significance. *Am J Surg Pathol* 1998;22:576-587. Available at: <http://www.ncbi.nlm.nih.gov/pubmed/9591728>.
14. Bowne WB, Antonescu CR, Leung DH, et al. Dermatofibrosarcoma protuberans: A clinicopathologic analysis of patients treated and followed at a single institution. *Cancer* 2000;88:2711-2720. Available at: <http://www.ncbi.nlm.nih.gov/pubmed/10870053>.
15. Goldblum JR, Reith JD, Weiss SW. Sarcomas arising in dermatofibrosarcoma protuberans: a reappraisal of biologic behavior in eighteen cases treated by wide local excision with extended clinical

follow up. Am J Surg Pathol 2000;24:1125-1130. Available at:
<http://www.ncbi.nlm.nih.gov/pubmed/10935653>.

16. Buck DW, 2nd, Kim JY, Alam M, et al. Multidisciplinary approach to the management of dermatofibrosarcoma protuberans. J Am Acad Dermatol 2012;67:861-866. Available at:
<http://www.ncbi.nlm.nih.gov/pubmed/22387033>.

17. Dawes KW, Hanke CW. Dermatofibrosarcoma protuberans treated with Mohs micrographic surgery: cure rates and surgical margins. Dermatol Surg 1996;22:530-534. Available at:
<http://www.ncbi.nlm.nih.gov/pubmed/8646467>.

18. DuBay D, Cimmino V, Lowe L, et al. Low recurrence rate after surgery for dermatofibrosarcoma protuberans: a multidisciplinary approach from a single institution. Cancer 2004;100:1008-1016. Available at: <http://www.ncbi.nlm.nih.gov/pubmed/14983497>.

19. Gloster HM, Jr., Harris KR, Roenigk RK. A comparison between Mohs micrographic surgery and wide surgical excision for the treatment of dermatofibrosarcoma protuberans. J Am Acad Dermatol 1996;35:82-87. Available at: <http://www.ncbi.nlm.nih.gov/pubmed/8682970>.

20. Haas AF, Sykes JM. Multispecialty approach to complex dermatofibrosarcoma protuberans of the forehead. Arch Otolaryngol Head Neck Surg 1998;124:324-327. Available at:
<http://www.ncbi.nlm.nih.gov/pubmed/9525519>.

21. Huether MJ, Zitelli JA, Brodland DG. Mohs micrographic surgery for the treatment of spindle cell tumors of the skin. J Am Acad Dermatol 2001;44:656-659. Available at:
<http://www.ncbi.nlm.nih.gov/pubmed/11260542>.

22. Pennington BE, Leffell DJ. Mohs micrographic surgery: established uses and emerging trends. Oncology (Williston Park) 2005;19:1165-1171; discussion 1171-1162, 1175. Available at:
<http://www.ncbi.nlm.nih.gov/pubmed/16255133>.

23. Sondak VK, Cimmino VM, Lowe LM, et al. Dermatofibrosarcoma protuberans: what is the best surgical approach? Surg Oncol 1999;8:183-189. Available at:
<http://www.ncbi.nlm.nih.gov/pubmed/11128831>.

24. Snow SN, Gordon EM, Larson PO, et al. Dermatofibrosarcoma protuberans: a report on 29 patients treated by Mohs micrographic surgery with long-term follow-up and review of the literature. Cancer 2004;101:28-38. Available at:
<http://www.ncbi.nlm.nih.gov/pubmed/15221986>.

25. Kimmel Z, Ratner D, Kim JY, et al. Peripheral excision margins for dermatofibrosarcoma protuberans: a meta-analysis of spatial data. Ann Surg Oncol 2007;14:2113-2120. Available at:
<http://www.ncbi.nlm.nih.gov/pubmed/17468914>.

26. Stojadinovic A, Karpoff HM, Antonescu CR, et al. Dermatofibrosarcoma protuberans of the head and neck. Ann Surg Oncol 2000;7:696-704. Available at:
<http://www.ncbi.nlm.nih.gov/pubmed/11034249>.

27. Farma JM, Ammori JB, Zager JS, et al. Dermatofibrosarcoma protuberans: how wide should we resect? Ann Surg Oncol 2010;17:2112-2118. Available at:
<http://www.ncbi.nlm.nih.gov/pubmed/20354798>.

28. Bogucki B, Neuhaus I, Hurst EA. Dermatofibrosarcoma Protuberans: A Review of the Literature. Dermatol Surg 2012. Available at: <http://www.ncbi.nlm.nih.gov/pubmed/22288484>.

29. Foroozan M, Sei JF, Amini M, et al. Efficacy of Mohs micrographic surgery for the treatment of dermatofibrosarcoma protuberans: systematic review. Arch Dermatol 2012;148:1055-1063. Available at:
<http://www.ncbi.nlm.nih.gov/pubmed/22986859>.

30. Meguerditchian AN, Wang J, Lema B, et al. Wide Excision or Mohs Micrographic Surgery for the Treatment of Primary

Dermatofibrosarcoma Protuberans. Am J Clin Oncol 2009. Available at: <http://www.ncbi.nlm.nih.gov/pubmed/19858696>.

31. McArthur G. Molecularly targeted treatment for dermatofibrosarcoma protuberans. Semin Oncol 2004;31:30-36. Available at: <http://www.ncbi.nlm.nih.gov/pubmed/15176002>.

32. Sjoblom T, Shimizu A, O'Brien KP, et al. Growth inhibition of dermatofibrosarcoma protuberans tumors by the platelet-derived growth factor receptor antagonist STI571 through induction of apoptosis. Cancer Res 2001;61:5778-5783. Available at: <http://www.ncbi.nlm.nih.gov/pubmed/11479215>.

33. Mendenhall WM, Zlotecki RA, Scarborough MT. Dermatofibrosarcoma protuberans. Cancer 2004;101:2503-2508. Available at: <http://www.ncbi.nlm.nih.gov/pubmed/15503305>.

34. Labropoulos SV, Fletcher JA, Oliveira AM, et al. Sustained complete remission of metastatic dermatofibrosarcoma protuberans with imatinib mesylate. Anticancer Drugs 2005;16:461-466. Available at: <http://www.ncbi.nlm.nih.gov/pubmed/15746584>.

35. McArthur GA, Demetri GD, van Oosterom A, et al. Molecular and Clinical Analysis of Locally Advanced Dermatofibrosarcoma Protuberans Treated With Imatinib: Imatinib Target Exploration Consortium Study B2225. J Clin Oncol 2005;23:866-873. Available at: <http://www.jco.org/cgi/content/abstract/23/4/866>.

36. Rubin BP, Schuetze SM, Eary JF, et al. Molecular Targeting of Platelet-Derived Growth Factor B by Imatinib Mesylate in a Patient With Metastatic Dermatofibrosarcoma Protuberans. J Clin Oncol 2002;20:3586-3591. Available at: <http://www.jco.org/cgi/content/abstract/20/17/3586>.

37. Ugurel S, Utikal J, Mohr P, et al. Imatinib in locally advanced dermatofibrosarcoma protuberans (DFSP): A phase II trial of the Dermatologic Cooperative Oncology Group (DeCOG) [abstract]. J Clin

Oncol 2006;24(Suppl 18):Abstract 9561. Available at: http://meeting.jco.org/cgi/content/abstract/24/18_suppl/9561.

38. Rutkowski P, Van Glabbeke M, Rankin CJ, et al. Imatinib mesylate in advanced dermatofibrosarcoma protuberans: pooled analysis of two phase II clinical trials. J Clin Oncol 2010;28:1772-1779. Available at: <http://www.ncbi.nlm.nih.gov/pubmed/20194851>.

39. McArthur GA. Molecular targeting of dermatofibrosarcoma protuberans: a new approach to a surgical disease. J Natl Compr Canc Netw 2007;5:557-562. Available at: <http://www.ncbi.nlm.nih.gov/pubmed/17509258>.

40. Suit H, Spiro I, Mankin HJ, et al. Radiation in management of patients with dermatofibrosarcoma protuberans. J Clin Oncol 1996;14:2365-2369. Available at: <http://www.ncbi.nlm.nih.gov/pubmed/8708729>.

41. Ballo MT, Zagars GK, Pisters P, Pollack A. The role of radiation therapy in the management of dermatofibrosarcoma protuberans. Int J Radiat Oncol Biol Phys 1998;40:823-827. Available at: <http://www.ncbi.nlm.nih.gov/pubmed/9531366>.

42. Dagan R, Morris CG, Zlotecki RA, et al. Radiotherapy in the treatment of dermatofibrosarcoma protuberans. Am J Clin Oncol 2005;28:537-539. Available at: <http://www.ncbi.nlm.nih.gov/pubmed/16317260>.

43. Sun LM, Wang CJ, Huang CC, et al. Dermatofibrosarcoma protuberans: treatment results of 35 cases. Radiother Oncol 2000;57:175-181. Available at: <http://www.ncbi.nlm.nih.gov/pubmed/11054521>.


44. Uysal B, Sager O, Gamsiz H, et al. Evaluation of the role of radiotherapy in the management of dermatofibrosarcoma protuberans. J BUON 2013;18:268-273. Available at: <http://www.ncbi.nlm.nih.gov/pubmed/23613415>.



45. Hamid R, Hafeez A, Darzi MA, et al. Outcome of wide local excision in dermatofibrosarcoma protuberans and use of radiotherapy for margin-positive disease. *Indian Dermatol Online J* 2013;4:93-96. Available at: <http://www.ncbi.nlm.nih.gov/pubmed/23741663>.

46. Castle KO, Guadagnolo BA, Tsai CJ, et al. Dermatofibrosarcoma protuberans: long-term outcomes of 53 patients treated with conservative surgery and radiation therapy. *Int J Radiat Oncol Biol Phys* 2013;86:585-590. Available at: <http://www.ncbi.nlm.nih.gov/pubmed/23628134>.

47. Williams N, Morris CG, Kirwan JM, et al. Radiotherapy for Dermatofibrosarcoma Protuberans. *Am J Clin Oncol* 2013. Available at: <http://www.ncbi.nlm.nih.gov/pubmed/23388563>.

A large, faint watermark consisting of two concentric circles. Inside the circles, the text "Discussion update in progress" is written in a large, light gray font, centered on the page.

Discussion
update in
progress