



National
Comprehensive
Cancer
Network®

NCCN Clinical Practice Guidelines in Oncology (NCCN Guidelines®)

Vulvar Cancer

(Squamous Cell Carcinoma)

Version 1.2018 — October 27, 2017

NCCN.org

Continue



National
Comprehensive
Cancer
Network®

NCCN Guidelines Version 1.2018 Panel Members

Vulvar Cancer (Squamous Cell Carcinoma)

[NCCN Guidelines Index](#)
[Table of Contents](#)
[Discussion](#)

***Wui-Jin Koh, MD/Chair §**
Fred Hutchinson Cancer Research
Center/Seattle Cancer Care Alliance

***Nadeem R. Abu-Rustum, MD Ω/Vice Chair**
Memorial Sloan Kettering Cancer Center

Sarah Bean, MD ≠
Duke Cancer Institute

Kristin Bradley, MD §
University of Wisconsin
Carbone Cancer Center

Susana M. Campos, MD, MPH, MS †
Dana-Farber/Brigham and Women's
Cancer Center

Kathleen R. Cho, MD ≠
University of Michigan
Comprehensive Cancer Center

Hye Sook Chon, MD Ω
Moffitt Cancer Center

Christina Chu, MD Ω
Fox Chase Cancer Center

David Cohn, MD Ω
The Ohio State University Comprehensive
Cancer Center - James Cancer Hospital
and Solove Research Institute

Marta Ann Crispens, MD Ω
Vanderbilt-Ingram Cancer Center

Shari Damast, MD §
Yale Cancer Center/Smilow Cancer Hospital

NCCN
Nicole McMillian, MS
Jillian Scavone, PhD

[NCCN Guidelines Panel Disclosures](#)

Oliver Dorigo, MD, PhD Ω
Stanford Cancer Institute

Patricia J. Eifel, MD §
The University of Texas
MD Anderson Cancer Center

Christine M. Fisher, MD, MPH §
University of Colorado Cancer Center

Peter Frederick, MD Ω
Roswell Park Cancer Institute

David K. Gaffney, MD, PhD §
Huntsman Cancer Institute
at the University of Utah

Ernest Han, MD, PhD Ω
City of Hope Comprehensive
Cancer Center

Susan Higgins, MD §
Yale Cancer Center/Smilow Cancer Hospital

Warner K. Huh, MD Ω
University of Alabama at Birmingham
Comprehensive Cancer Center

John R. Lurain, III, MD Ω
Robert H. Lurie Comprehensive Cancer
Center of Northwestern University

Andrea Mariani, MD Ω
Mayo Clinic Cancer Center

David Mutch, MD Ω
Siteman Cancer Center at Barnes-
Jewish Hospital and Washington
University School of Medicine

Christa Nagel, MD Ω
Case Comprehensive Cancer Center/University
Hospitals Seidman Cancer Center and Cleveland
Clinic Taussig Cancer Institute

Larissa Nekhlyudov, MD, MPH
Dana-Farber/Brigham and Women's Cancer Center

Amanda Nickles Fader, MD Ω
The Sidney Kimmel Comprehensive
Cancer Center at Johns Hopkins

Steven W. Remmenga, MD Ω
Fred & Pamela Buffett Cancer Center

R. Kevin Reynolds, MD Ω
University of Michigan
Comprehensive Cancer Center

Todd Tillmanns, MD Ω
St. Jude Children's Research Hospital/
University of Tennessee Health Science Center

Stefanie Ueda, MD Ω
UCSF Helen Diller Family
Comprehensive Cancer Center

Emily Wyse
Patient Advocate

Catheryn M. Yashar, MD §
UC San Diego Moores Cancer Center

Ω Gynecologic oncology
† Medical oncology
§ Radiotherapy/Radiation oncology
≠ Pathology
* Discussion Section Writing committee

Continue



National
Comprehensive
Cancer
Network®

NCCN Guidelines Version 1.2018 Sub-Committees

Vulvar Cancer (Squamous Cell Carcinoma)

[NCCN Guidelines Index](#)
[Table of Contents](#)
[Discussion](#)

Principles of Surgery

Amanda Nickles Fader, MD Ω/Lead
The Sidney Kimmel Comprehensive
Cancer Center at Johns Hopkins

Nadeem R. Abu-Rustum, MD Ω
Memorial Sloan Kettering Cancer Center

Ernest Han, MD, PhD Ω
City of Hope
Comprehensive Cancer Center

Warner K. Huh, MD Ω
University of Alabama at Birmingham
Comprehensive Cancer Center

David Mutch, MD Ω
Siteman Cancer Center at Barnes-
Jewish Hospital and Washington
University School of Medicine

Systemic Therapy

R. Kevin Reynolds, MD Ω
University of Michigan
Comprehensive Cancer Center

Principles of Radiation

Catheryn M. Yashar, MD §/Co-Lead
UC San Diego Moores Cancer Center

Christine M. Fisher, MD, MPH §/Co-Lead
University of Colorado Cancer Center

Kristin Bradley, MD §
University of Wisconsin
Carbone Cancer Center

Shari Damast, MD §
Yale Cancer Center/Smilow Cancer Hospital

Patricia J. Eifel, MD §
The University of Texas
MD Anderson Cancer Center

David K. Gaffney, MD, PhD §
Huntsman Cancer Institute
at the University of Utah

Wui-Jin Koh, MD §
Fred Hutchinson Cancer Research Center/
Seattle Cancer Care Alliance

Principles of Imaging*

Nadeem R. Abu-Rustum, MD Ω/Lead
Memorial Sloan Kettering Cancer Center

Hye Sook Chon, MD, MS Ω
Moffitt Cancer Center

Christina Chu, MD Ω
Fox Chase Cancer Center

Christine M. Fisher, MD, MPH §
University of Colorado Cancer Center

David K. Gaffney, MD, PhD §
Huntsman Cancer Institute
at the University of Utah

Ernest Han, MD, PhD Ω
City of Hope Comprehensive
Cancer Center

Andrea Mariani, MD Ω
Mayo Clinic Cancer Center

Larissa Nekhlyudov, MD, MPH
Dana-Farber/Brigham and Women's
Cancer Center

Continue

φ Diagnostic Radiology
Ω Gynecologic oncology
† Medical oncology
§ Radiotherapy/Radiation oncology

[NCCN Guidelines Panel Disclosures](#)



National
Comprehensive
Cancer
Network®

NCCN Guidelines Version 1.2018 Table of Contents

Vulvar Cancer (Squamous Cell Carcinoma)

[NCCN Guidelines Index](#)
[Table of Contents](#)
[Discussion](#)

[NCCN Vulvar Cancer Panel Members](#)

[NCCN Vulvar Cancer Sub-Committee Members](#)

[Summary of the Guidelines Updates](#)

[Workup \(VULVA-1\)](#)

[Early Stage: T1, Smaller T2 \(VULVA-2\)](#)

[Adjuvant Therapy Based On Primary Tumor Risk Factors \(VULVA-3\)](#)

[Adjuvant Therapy Based On Nodal Status \(VULVA-4\)](#)

[Locally Advanced: Larger T2, T3 \(VULVA-5\)](#)

[Additional Treatment \(VULVA-6\)](#)

[Metastatic Disease Beyond Pelvis: Any T, Any N, M1 \(VULVA-7\)](#)

[Surveillance \(VULVA-8\)](#)

[Therapy for Recurrence Clinically Limited to the Vulva \(VULVA-9\)](#)

[Therapy for Clinical Nodal or Distant Recurrence \(VULVA-10\)](#)

[Principles of Imaging \(VULVA-A\)](#)

[Principles of Surgery \(VULVA-B\)](#)

[Principles of Radiation Therapy \(VULVA-C\)](#)

[Systemic Therapy \(VULVA-D\)](#)

[Staging \(ST-1\)](#)

Clinical Trials: NCCN believes that the best management for any patient with cancer is in a clinical trial. Participation in clinical trials is especially encouraged.

To find clinical trials online at NCCN Member Institutions, [click here: nccn.org/clinical_trials/physician.html](#).

NCCN Categories of Evidence and Consensus: All recommendations are category 2A unless otherwise indicated.

See [NCCN Categories of Evidence and Consensus](#).

For vulvar melanoma see the [NCCN Guidelines for Melanoma](#)

The NCCN Guidelines® are a statement of evidence and consensus of the authors regarding their views of currently accepted approaches to treatment. Any clinician seeking to apply or consult the NCCN Guidelines is expected to use independent medical judgment in the context of individual clinical circumstances to determine any patient's care or treatment. The National Comprehensive Cancer Network® (NCCN®) makes no representations or warranties of any kind regarding their content, use or application and disclaims any responsibility for their application or use in any way. The NCCN Guidelines are copyrighted by National Comprehensive Cancer Network®. All rights reserved. The NCCN Guidelines and the illustrations herein may not be reproduced in any form without the express written permission of NCCN. ©2017.



NCCN Guidelines Version 1.2018 Updates Vulvar Cancer (Squamous Cell Carcinoma)

Updates in Version 1.2018 of the NCCN Guidelines for Vulvar Cancer from Version 1.2017 include:

Global changes

- “Clinical trial” was removed throughout the algorithm, but is still listed as part of the NCCN Clinical Trials footer box noted on all pages.
- “Chemotherapy” changed to “Systemic therapy” where appropriate.
- The AJCC Cancer Staging tables (7th edition) were updated to the 8th edition for carcinoma of the vulva. ([ST-1](#))

VULVA-1

- Workup: “Consider HIV testing” added with corresponding footnote “c” stating “Consider HIV testing, especially in younger patients. Patients with cervical cancer and HIV should be referred to an HIV specialist and should be treated for vulvar cancer as per these guidelines. Modifications to cancer treatment should not be made solely on the basis of HIV status.”

VULVA-2

- “Pathologic Findings” revised as follows:
 - ▶ “T1a (≤ 1 mm invasion)”
 - ▶ “T1b (> 1 mm invasion) or T2”

VULVA-4

- Footnote “I” regarding SLN(s) positive findings is new “If ipsilateral groin is positive, the contralateral groin should be evaluated surgically and/or treated with EBRT.”

VULVA-8

- Footnote “r” reference updated: “Salani R, Khanna N, Frimer M, et al. An update on post-treatment surveillance and diagnosis of recurrence in women with gynecologic malignancies: Society of Gynecologic Oncology (SGO) recommendations. Gynecol Oncol 2017;146:3-10.”

VULVA-9

- Therapy for Relapse after “Radical excision and unilateral or bilateral inguofemoral LN dissection”: “EBRT” added as an option for “Margins negative; LN(s) surgically or clinically negative.”

VULVA-10

- Therapy for Recurrence: After “No prior EBRT” the “Unresectable node(s)” pathway was removed.

[Continued](#)

UPDATES
1 OF 2



NCCN Guidelines Version 1.2018 Updates

Vulvar Cancer (Squamous Cell Carcinoma)

VULVA-A Principles of Imaging

- Follow-up/Surveillance

- ▶ First bullet revised: “*CT chest/abdomen/pelvis or whole body PET/CT may be performed if recurrence/metastasis is suspected.*”
- ▶ Bullet removed: “For patients with locally advanced and/or node-positive disease, optional chest/abdominal/pelvic CT every 6–12 months for 2–3 years.”

VULVA-C Principles of Radiation Therapy

- This section was extensively revised.

VULVA-D Systemic Therapy

- Chemotherapy for Advanced, Recurrent/Metastatic Disease

- ▶ Carboplatin/paclitaxel changed from category 2B to *category 2A*
- ▶ Paclitaxel changed from category 2B to *category 2A*
- ▶ *Cisplatin/gemcitabine* added as a category 2B recommendation
- ▶ “*Pembrolizumab* (second-line therapy for MSI-H/dMMR tumors)” added as a category 2B recommendation
- New reference “3” footnote added for erlotinib: “*Horowitz NS, Olawaiye AB, Borger DR, et al. Phase II trial of erlotinib in women with squamous cell carcinoma of the vulva. Gynecol Oncol 2012;127:141-146.*”



NCCN Guidelines Version 1.2018

Vulvar Cancer (Squamous Cell Carcinoma)

SQUAMOUS CELL CARCINOMA^a

WORKUP

- H&P
- CBC
- Biopsy, pathologic review
- LFT/renal function studies
- Imaging^b as needed for delineating extent of tumor or for treatment planning
- EUA cystoscopy or proctoscopy as indicated
- Smoking cessation and counseling intervention if indicated ([See NCCN Guidelines for Smoking Cessation](#))
- Consider HPV testing
- Consider HIV testing^c

CLINICAL STAGE

PRIMARY TREATMENT

Early Stage
(T1, Smaller T2^d)

[See Primary Treatment \(VULVA-2\)](#)

Locally advanced
(Larger T2, T3:
non-visceral-sparing
primary surgery)

[See Primary Treatment \(VULVA-5\)](#)

Metastatic disease beyond pelvis
(Any T, Any N, M1 beyond pelvis)

[See Primary Treatment \(VULVA-7\)](#)

^aHistologic high-grade squamous intraepithelial lesion (HSIL; formerly defined as carcinoma in situ [CIS] and incorporates vulvar intraepithelial neoplasia 2 and 3 [VIN2/3]) can be treated with wide local excision.

^b[See Principles of Imaging \(VULVA-A\)](#).

^cConsider HIV testing, especially in younger patients. Patients with cervical cancer and HIV should be referred to an HIV specialist and should be treated for vulvar cancer as per these guidelines. Modifications to cancer treatment should not be made solely on the basis of HIV status.

^dSmaller T2 tumors: ≤4 cm.

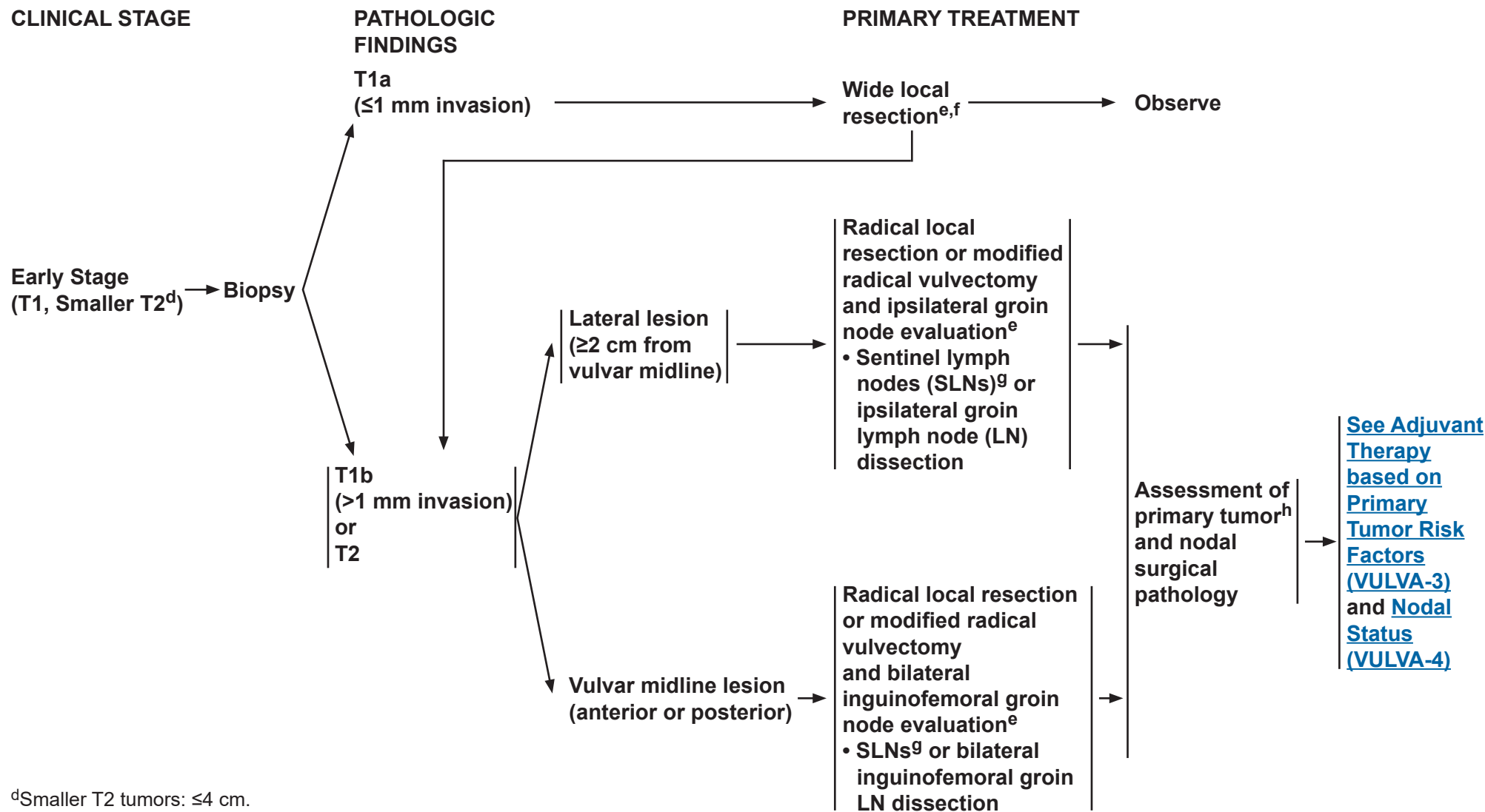
Note: All recommendations are category 2A unless otherwise indicated.

Clinical Trials: NCCN believes that the best management of any patient with cancer is in a clinical trial. Participation in clinical trials is especially encouraged.



NCCN Guidelines Version 1.2018

Vulvar Cancer (Squamous Cell Carcinoma)



^dSmaller T2 tumors: ≤4 cm.

^e[See Principles of Surgery \(VULVA-B\).](#)

^fIf wide local resection pathology reveals tumor in aggregate of ≥1 mm invasion, then additional surgery may be warranted.

^gGroin node dissection is required on side(s) where sentinel nodes are not detected.

^h[See Principles of Surgery: Tumor Margin Status \(VULVA-B 1 of 4\).](#)

Note: All recommendations are category 2A unless otherwise indicated.

Clinical Trials: NCCN believes that the best management of any patient with cancer is in a clinical trial. Participation in clinical trials is especially encouraged.

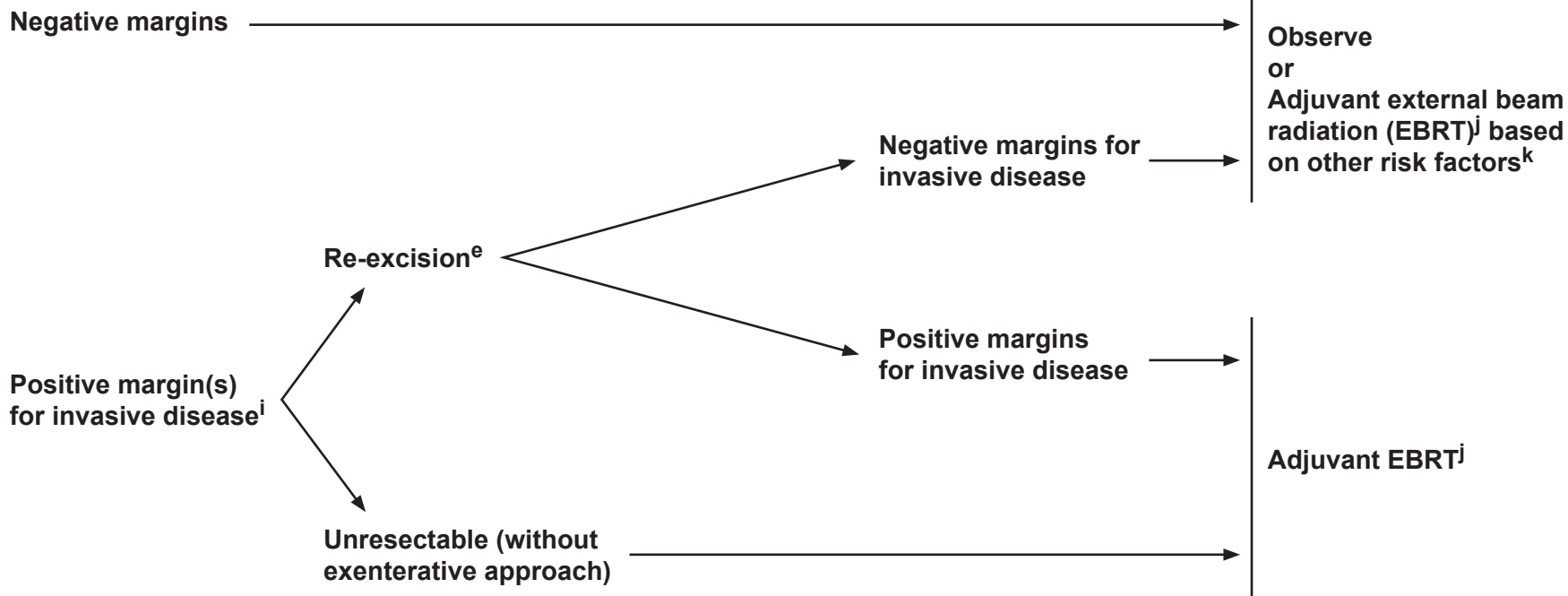


NCCN Guidelines Version 1.2018

Vulvar Cancer (Squamous Cell Carcinoma)

PRIMARY TUMOR RISK FACTORS

ADJUVANT THERAPY TO THE PRIMARY SITE



^e[See Principles of Surgery \(VULVA-B\).](#)

ⁱThe management of positive margins for HSIL (non-invasive disease) should be individualized.

^j[See Principles of Radiation Therapy \(VULVA-C\).](#)

^kOther primary risk factors include: lymphovascular invasion, negative but close tumor margins (<8 mm), tumor size, depth of invasion, and pattern of invasion (spray or diffuse). Nodal involvement (as an indicator of lymphovascular space invasion) may also impact selection of adjuvant therapy to the primary site.

Note: All recommendations are category 2A unless otherwise indicated.

Clinical Trials: NCCN believes that the best management of any patient with cancer is in a clinical trial. Participation in clinical trials is especially encouraged.

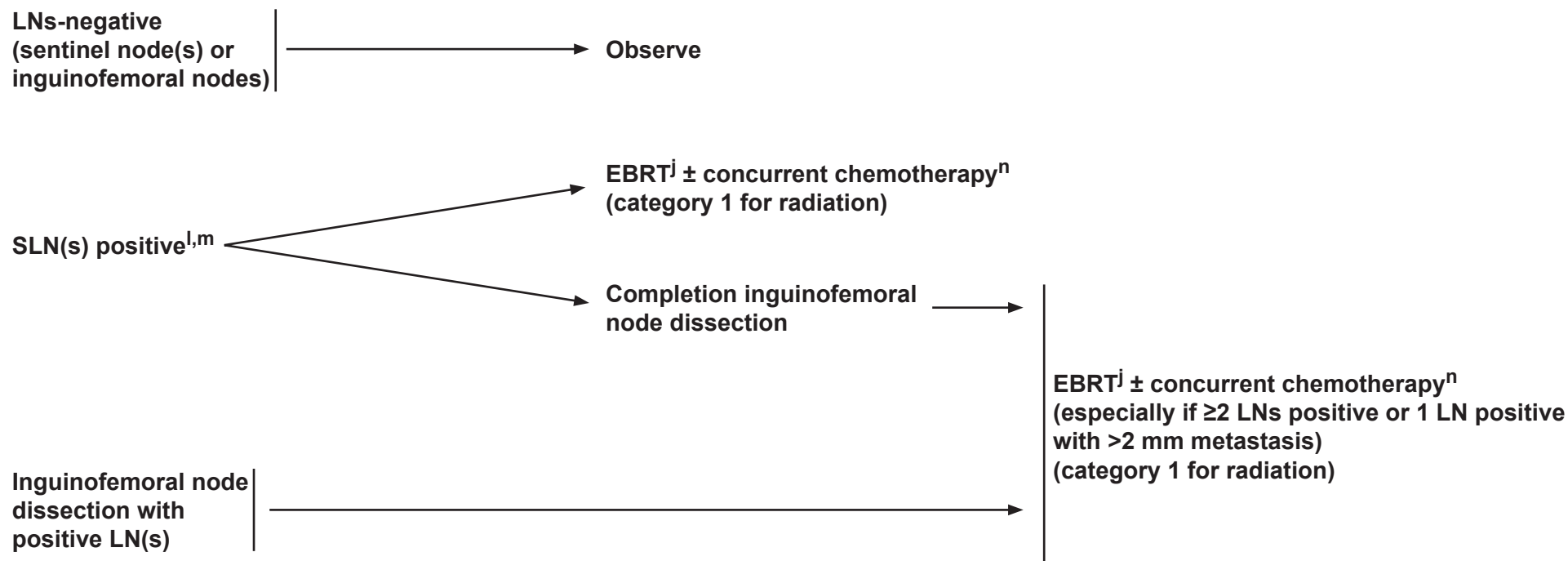


NCCN Guidelines Version 1.2018

Vulvar Cancer (Squamous Cell Carcinoma)

NODAL EVALUATION

ADJUVANT THERAPY TO THE NODES



^jSee Principles of Radiation Therapy (VULVA-C).

^lIf ipsilateral groin is positive, the contralateral groin should be evaluated surgically and/or treated with EBRT.

^mSee Principles of Surgery: Inguinofemoral Sentinel Lymph Node Procedure (VULVA-B 3 of 4).

ⁿSee Systemic Therapy (VULVA-D).

Note: All recommendations are category 2A unless otherwise indicated.

Clinical Trials: NCCN believes that the best management of any patient with cancer is in a clinical trial. Participation in clinical trials is especially encouraged.

[See
Surveillance
\(VULVA-8\)](#)



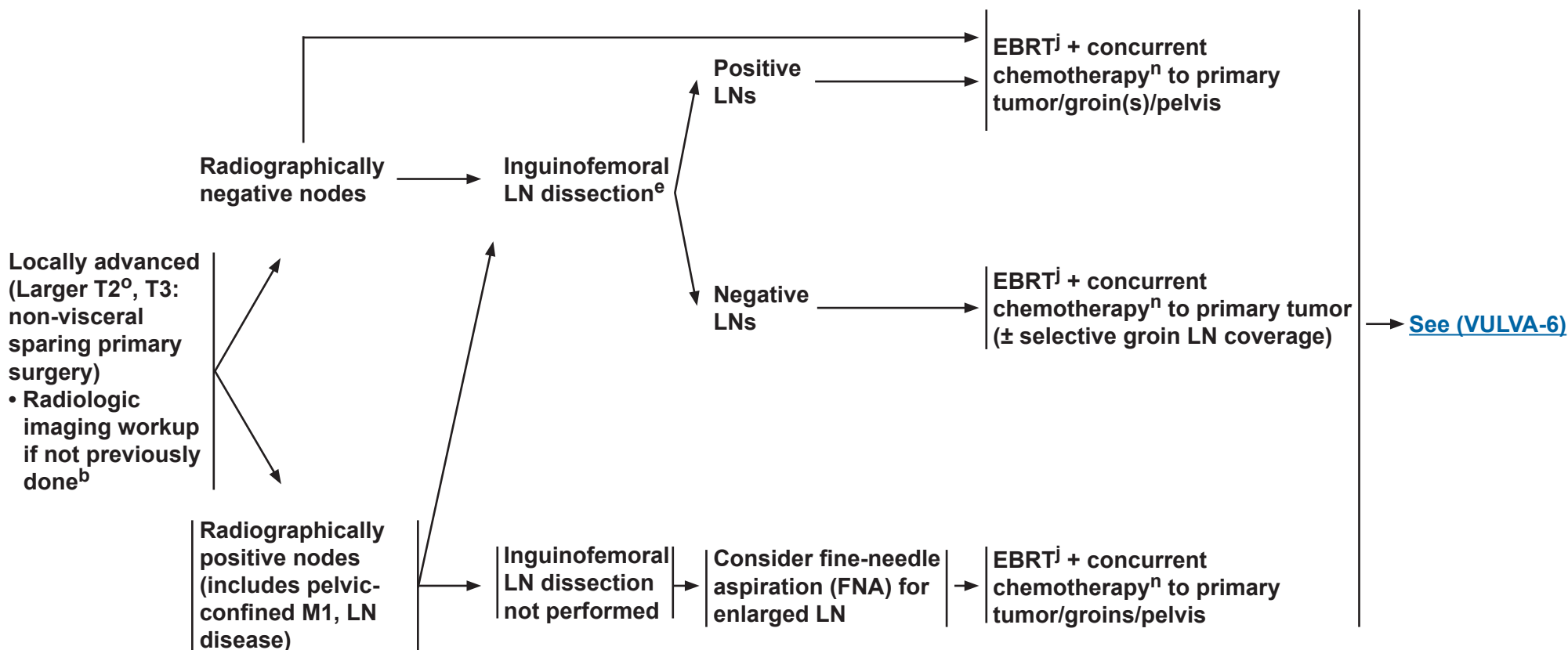
NCCN Guidelines Version 1.2018

Vulvar Cancer (Squamous Cell Carcinoma)

CLINICAL STAGE

PRIMARY TREATMENT

ADDITIONAL TREATMENT



^bSee Principles of Imaging (VULVA-A).

^eSee Principles of Surgery (VULVA-B).

^jSee Principles of Radiation Therapy (VULVA-C).

ⁿSee Systemic Therapy (VULVA-D).

^oLarger T2 tumors: >4 cm or with involvement of the urethra, vagina, or anus.

Note: All recommendations are category 2A unless otherwise indicated.

Clinical Trials: NCCN believes that the best management of any patient with cancer is in a clinical trial. Participation in clinical trials is especially encouraged.

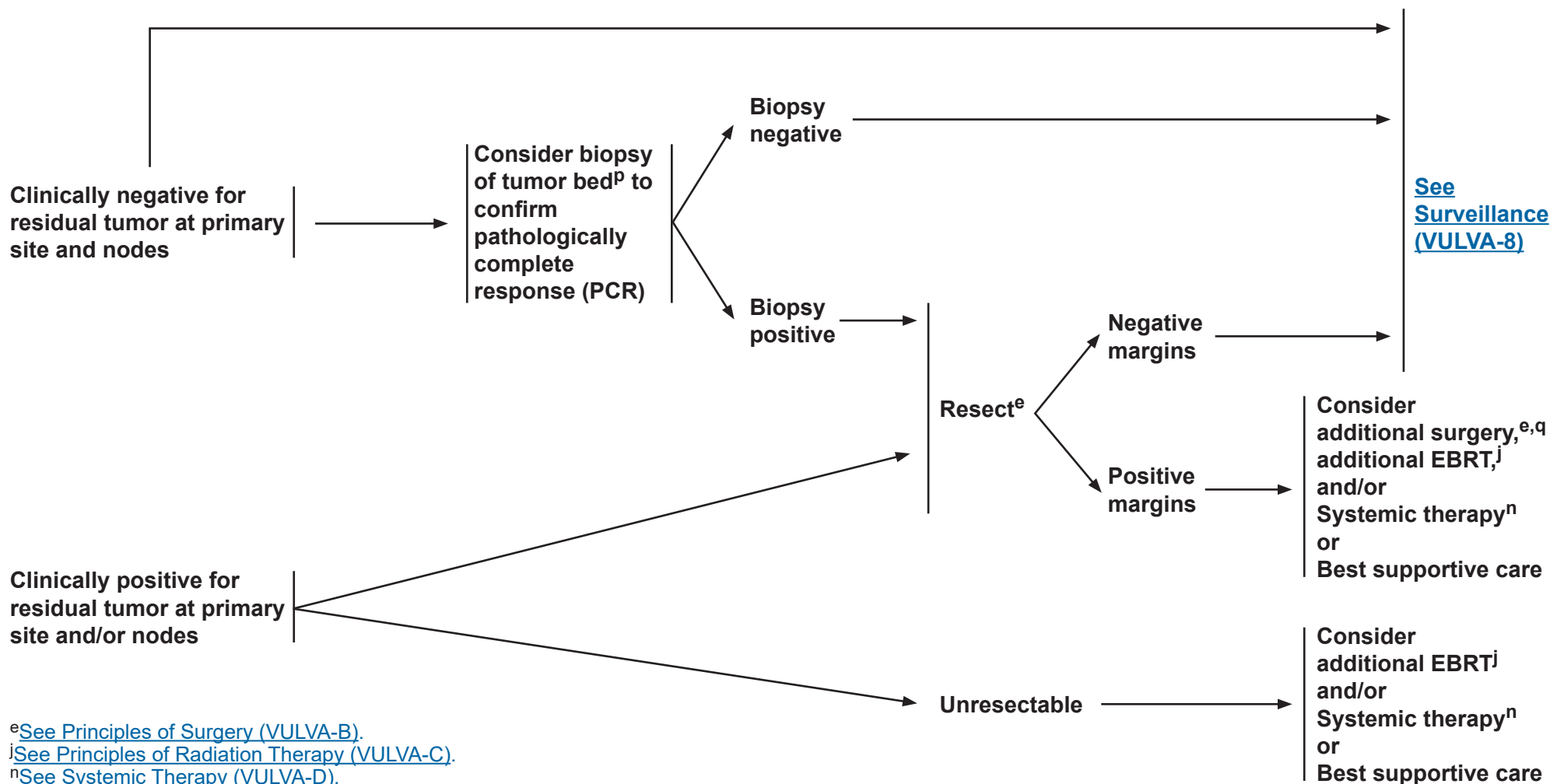


NCCN Guidelines Version 1.2018

Vulvar Cancer (Squamous Cell Carcinoma)

EVALUATION OF RESPONSE TO EBRT + CONCURRENT CHEMOTHERAPY

ADDITIONAL TREATMENT



^eSee Principles of Surgery (VULVA-B).

^jSee Principles of Radiation Therapy (VULVA-C).

ⁿSee Systemic Therapy (VULVA-D).

^PNo sooner than 3 months from completion of treatment.

^qConsider pelvic exenteration for select cases with a central recurrence.

Note: All recommendations are category 2A unless otherwise indicated.

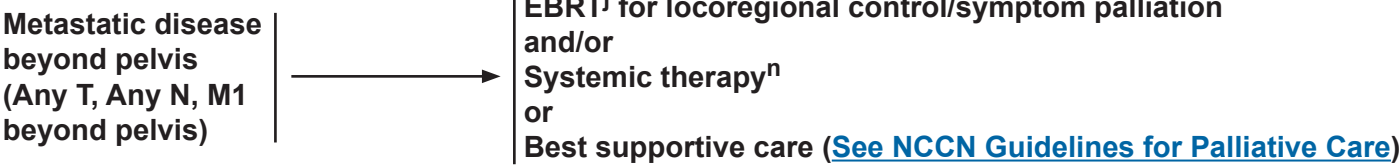
Clinical Trials: NCCN believes that the best management of any patient with cancer is in a clinical trial. Participation in clinical trials is especially encouraged.

NCCN Guidelines Version 1.2018

Vulvar Cancer (Squamous Cell Carcinoma)

CLINICAL STAGE

PRIMARY TREATMENT



^j[See Principles of Radiation Therapy \(VULVA-C\).](#)
ⁿ[See Systemic Therapy \(VULVA-D\).](#)

Note: All recommendations are category 2A unless otherwise indicated.
Clinical Trials: NCCN believes that the best management of any patient with cancer is in a clinical trial. Participation in clinical trials is especially encouraged.



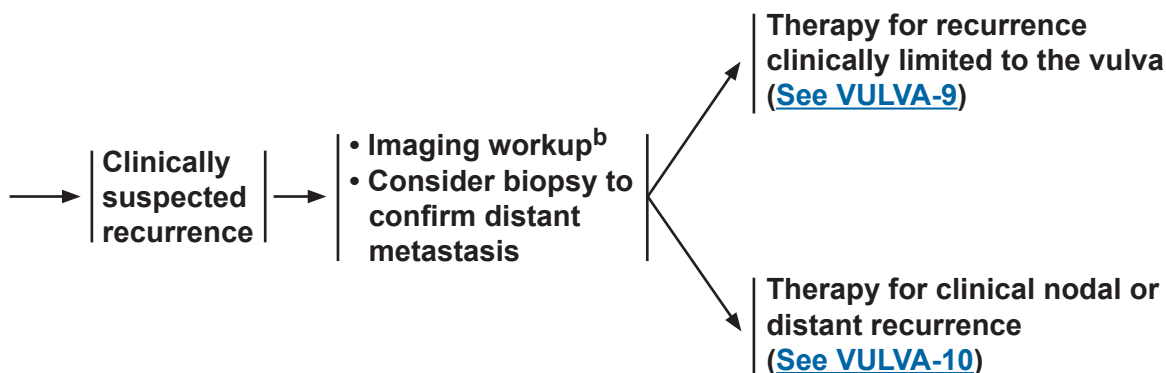
NCCN Guidelines Version 1.2018

Vulvar Cancer (Squamous Cell Carcinoma)

SURVEILLANCE^r

- Interval H&P every 3–6 mo for 2 y, every 6–12 mo for 3–5 y, then annually based on patient's risk of disease recurrence
- Cervical/vaginal cytology screening^s as indicated for the detection of lower genital tract neoplasia
- Imaging as indicated based on symptoms or examination findings suspicious for recurrence^b
- Laboratory assessment (CBC, blood urea nitrogen [BUN], creatinine) as indicated based on symptoms or examination findings suspicious for recurrence
- Patient education regarding symptoms of potential recurrence and vulvar dystrophy, periodic self-examinations, lifestyle, obesity, exercise, sexual health (including vaginal dilator use and lubricants/moisturizers), smoking cessation, nutrition counseling, potential long-term and late effects of treatment ([See NCCN Guidelines for Survivorship](#) and [NCCN Guidelines for Smoking Cessation](#))

WORKUP



^b[See Principles of Imaging \(VULVA-A\).](#)

^rSalani R, Khanna N, Frimer M, et al. An update on post-treatment surveillance and diagnosis of recurrence in women with gynecologic malignancies: Society of Gynecologic Oncology (SGO) recommendations. *Gynecol Oncol* 2017;146:3-10.

^sRegular cytology can be considered for detection of lower genital tract dysplasia, although its value in detection of recurrent genital tract cancer is limited. The likelihood of picking up asymptomatic recurrences by cytology alone is low.

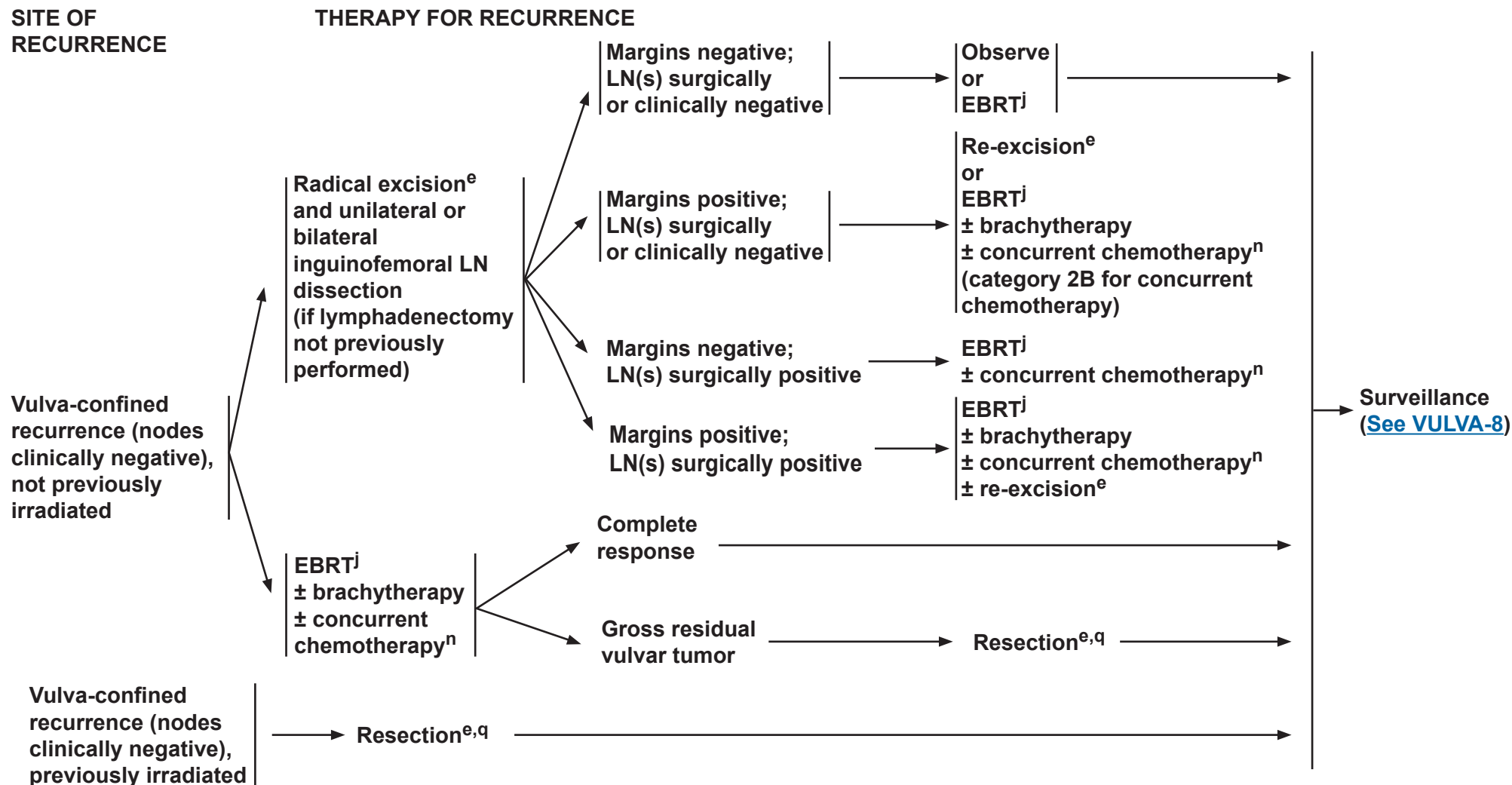
Note: All recommendations are category 2A unless otherwise indicated.

Clinical Trials: NCCN believes that the best management of any patient with cancer is in a clinical trial. Participation in clinical trials is especially encouraged.



NCCN Guidelines Version 1.2018

Vulvar Cancer (Squamous Cell Carcinoma)



^eSee Principles of Surgery (VULVA-B).

^jSee Principles of Radiation Therapy (VULVA-C).

ⁿSee Systemic Therapy (VULVA-D).

^qConsider pelvic exenteration for select cases with a central recurrence.

Note: All recommendations are category 2A unless otherwise indicated.

Clinical Trials: NCCN believes that the best management of any patient with cancer is in a clinical trial. Participation in clinical trials is especially encouraged.

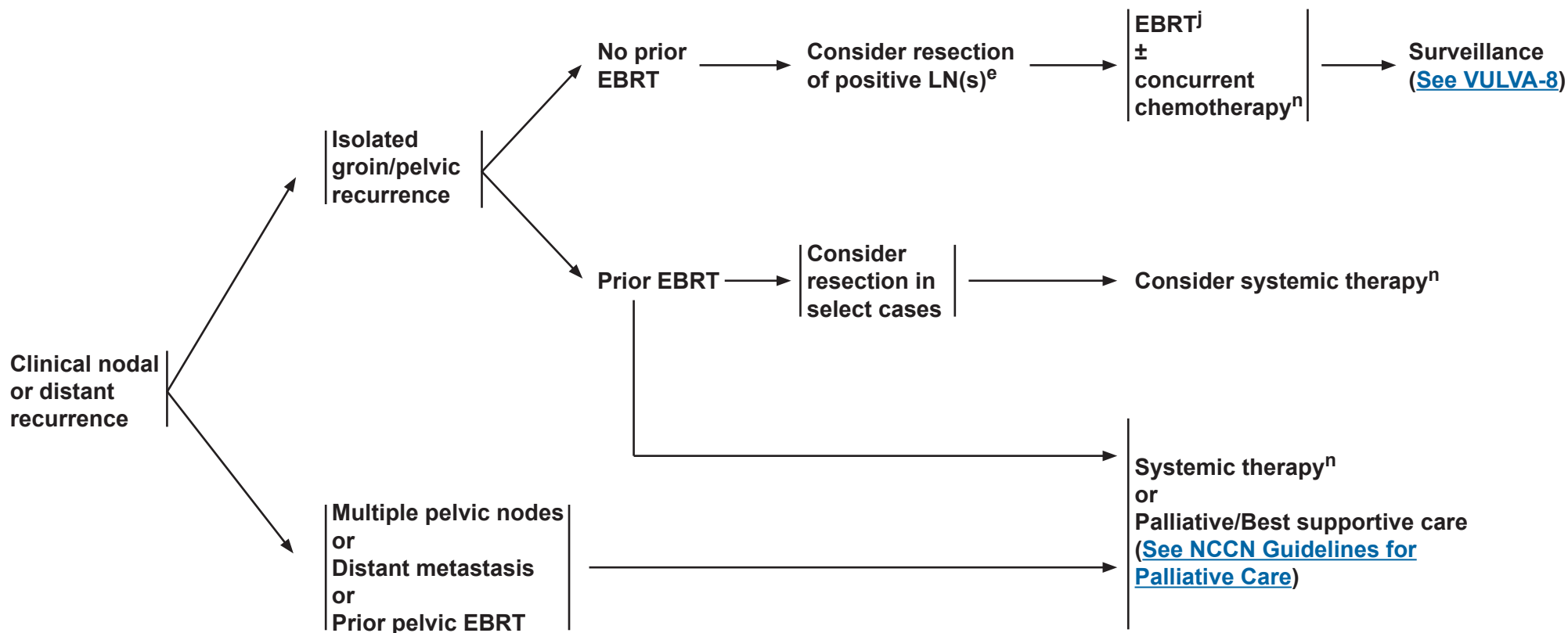


NCCN Guidelines Version 1.2018

Vulvar Cancer (Squamous Cell Carcinoma)

SITE OF RECURRENCE

THERAPY FOR RECURRENCE



^eSee Principles of Surgery (VULVA-B).

^jSee Principles of Radiation Therapy (VULVA-C).

ⁿSee Systemic Therapy (VULVA-D).

Note: All recommendations are category 2A unless otherwise indicated.

Clinical Trials: NCCN believes that the best management of any patient with cancer is in a clinical trial. Participation in clinical trials is especially encouraged.



NCCN Guidelines Version 1.2018

Vulvar Cancer (Squamous Cell Carcinoma)

PRINCIPLES OF IMAGING^{*,1-5}

Initial Workup

- Consider chest imaging with plain radiography (chest x-ray). If an abnormality is seen then chest CT without contrast may be performed.
- Consider pelvic MRI to aid in surgical and/or radiation treatment planning.**
- Consider whole body PET/CT or chest/abdomen/pelvic CT for T2 or larger tumors or if metastasis is suspected.**
- Other initial imaging should be based on symptomatology and clinical concern for metastatic disease.**

Follow-up/Surveillance

- CT chest/abdomen/pelvis or whole body PET/CT if recurrence/metastasis is suspected.***
- Other imaging should be based on symptomatology and clinical concern for recurrent/metastatic disease.***

Imaging for Documented Recurrence

- Consider whole body PET/CT if not previously performed during surveillance.
- Consider pelvic MRI to aid in further treatment planning.

*MRI and CT are performed with contrast throughout the guidelines unless contraindicated. Contrast is not required for screening chest CT.

**Indications may include abnormal physical exam findings; bulky vulvar tumor (≥4 cm or close to critical structures); vaginal, urethral, or anal involvement; delay in presentation or treatment; and pelvic, abdominal, or pulmonary symptoms.

***Indications may include abnormal physical exam findings such as palpable new mass or adenopathy, or new pelvic, abdominal, or pulmonary symptoms.

Note: All recommendations are category 2A unless otherwise indicated.

Clinical Trials: NCCN believes that the best management of any patient with cancer is in a clinical trial. Participation in clinical trials is especially encouraged.



NCCN Guidelines Version 1.2018

Vulvar Cancer (Squamous Cell Carcinoma)

PRINCIPLES OF IMAGING (References)

- ¹Salani R, Khanna N, Frimer M, et al. An update on post-treatment surveillance and diagnosis of recurrence in women with gynecologic malignancies: Society of Gynecologic Oncology (SGO) recommendations. *Gynecol Oncol* 2017;146:3-10.
- ²Kataoka MY, Sala E, Baldwin P, et al. The accuracy of magnetic resonance imaging in staging of vulvar cancer: a retrospective multi-centre study. *Gynecol Oncol* 2010;117:82-87.
- ³Robertson NL, Hricak H, Sonoda Y, et al. The impact of FDG-PET/CT in the management of patients with vulvar and vaginal cancer. *Gynec Oncol* 2016;140:420-424.
- ⁴Elit L, Reade CJ. Recommendations for follow-up care for gynecologic cancer survivors. *Obstet Gynecol* 2015;126:1207-1214.
- ⁵Viswanathan C, Kirschner K, Truong M, et al. Multimodality imaging of vulvar cancer: staging, therapeutic response, and complications. *AJR* 2013; 200:1387-1400.

Note: All recommendations are category 2A unless otherwise indicated.

Clinical Trials: NCCN believes that the best management of any patient with cancer is in a clinical trial. Participation in clinical trials is especially encouraged.



NCCN Guidelines Version 1.2018

Vulvar Cancer (Squamous Cell Carcinoma)

PRINCIPLES OF SURGERY: TUMOR MARGIN STATUS

- Studies suggest a high overall incidence of local recurrence in vulvar carcinoma.¹ Tumor margin of resection has been postulated as a significant prognostic factor for recurrence in squamous cell carcinoma of the vulva.^{2,3}
- Efforts should be made to obtain adequate surgical margins (1–2 cm) at primary surgery.
- In the setting of a close or positive surgical tumor margin (<8 mm from tumor), re-resection may be considered to obtain more adequate margins. Adjuvant local radiation therapy is another alternative.⁴ The risk-benefit ratio and morbidity of these approaches must be considered and individualized in each patient.^a
- Close or positive margins that involve the urethra, anus, or vagina may not be resectable without incurring significant potential morbidity and adverse impact on patient quality of life.
- Other factors including nodal status should be considered in the decision whether to perform subsequent surgery. Re-resection of close or positive vulvar tumor margins may not be beneficial in patients with metastases to the inguinal nodes that require treatment with EBRT ± chemotherapy after surgery.
- Pathologists often have a challenging time assessing the presence and depth of invasion in vulvar SCC. The depth of stromal invasion is currently defined as the measurement of the tumor from the epithelial-stromal junction of the adjacent most superficial dermal papilla to the deepest point of invasion. Alternative ways to measure the depth of invasion have recently been proposed.⁵

^aFor margins that are free but close (>0 mm but <8 mm), evidence is lacking to support decreased recurrence and improved survival with re-resection of disease or adjuvant local radiation to the primary tumor site.^{2,4}

Note: All recommendations are category 2A unless otherwise indicated.

Clinical Trials: NCCN believes that the best management of any patient with cancer is in a clinical trial. Participation in clinical trials is especially encouraged.



NCCN Guidelines Version 1.2018

Vulvar Cancer (Squamous Cell Carcinoma)

PRINCIPLES OF SURGERY: SURGICAL STAGING

- Vulvar cancer is staged using the American Joint Committee on Cancer (AJCC) and the International Federation of Gynecology and Obstetrics (FIGO) staging systems ([Table ST-1](#)).^{6,7}
- Staging involves complete surgical resection of the primary vulvar tumor(s) with at least 1-cm margins and either a unilateral or bilateral inguinofemoral lymphadenectomy, or an SLN biopsy in select patients. Inguinofemoral lymphadenectomy removes the LNs superficial to the inguinal ligament, within the proximal femoral triangle, and deep to the cribriform fascia.
- LN status is the most important determinant of survival.⁸
- Historically, en bloc resection of the vulvar tumor and complete bilateral inguinofemoral lymphadenectomy (resection of superficial inguinal and deep femoral nodes) were performed, but this approach was associated with significant morbidity.⁹
- The current standard involves resection of the vulvar tumor and LNs through separate incisions.⁹
- The choice of vulvar tumor resection technique depends on the size and extent of the primary lesion and may include radical local excision and modified radical vulvectomy.
- The depth of the resection is similar for both radical local excision and radical vulvectomy (ie, to the urogenital diaphragm).¹⁰
- There are no prospective trials comparing the resection techniques above. Retrospective data suggest there is no difference in recurrence outcome between radical local excision compared with radical vulvectomy.
- For a primary vulvar tumor that is <4 cm, located 2 cm or more from the vulvar midline and in the setting of clinically negative inguinofemoral LNs, a unilateral inguinofemoral lymphadenectomy or SLN biopsy is appropriate ([See Principles of Surgery: Inguinofemoral Sentinel Lymph Node Biopsy VULVA-B 3 of 4](#)).¹¹
- For a primary vulvar tumor located within 2 cm from or crossing the vulvar midline, a bilateral inguinofemoral lymphadenectomy¹¹ or SLN biopsy is recommended.
- Some patients are not candidates for lymphadenectomy including those with stage IA disease due to a <1% risk of lymphatic metastases.¹¹
- For patients with stage IB-II disease, inguinal lymphadenectomy is recommended due to a risk of >8% of lymphatic metastases.¹¹
- A negative unilateral lymphadenectomy is associated with <3% risk of contralateral metastases.¹²
- In the setting of positive LN disease after unilateral lymphadenectomy, contralateral lymphadenectomy⁸ or radiation of the contralateral groin is recommended. Any nodes that are grossly enlarged or suspicious for metastases during the unilateral lymphadenectomy should be evaluated by frozen section pathology intraoperatively in order to tailor the extent and bilaterality of the LN dissection.
- Those with locally advanced disease may benefit from neoadjuvant radiation with concurrent platinum-based radiosensitizing chemotherapy. If a complete response is not achieved, surgical resection of the residual disease is recommended in patients with resectable disease who are appropriate surgical candidates.¹¹
- The management of bulky inguinofemoral LNs in the setting of an unresectable or T3 primary vulvar lesion is unclear. It is reasonable to consider either 1) primary cytoreductive surgery of the bulky LNs followed by platinum-based chemosensitizing radiation to the bilateral groins and primary vulvar tumor, or 2) platinum-based chemosensitizing radiation to the bilateral groins and primary vulvar tumor alone.¹³

Note: All recommendations are category 2A unless otherwise indicated.

Clinical Trials: NCCN believes that the best management of any patient with cancer is in a clinical trial. Participation in clinical trials is especially encouraged.



NCCN Guidelines Version 1.2018

Vulvar Cancer (Squamous Cell Carcinoma)

PRINCIPLES OF SURGERY: INGUINFEMORAL SENTINEL LYMPH NODE BIOPSY

- Unilateral or bilateral inguinal lymphadenectomy is associated with a high rate of postoperative morbidity; 20%–40% of patients are at risk for wound complications and 30%–70% of patients are at risk of lymphedema.¹⁴
- Increasing evidence suggests that the use of SLN biopsy of the inguinofemoral LN basin is an alternative standard-of-care approach to lymphadenectomy in select women with squamous cell carcinoma of the vulva.^{15,16}
- SLN biopsy results in decreased postoperative morbidity without compromising detection of LN metastases.^{15,17}
- Prospective, cooperative group trials have evaluated the SLN technique and demonstrate feasibility, safety, validity, and a low risk of groin recurrences with this surgical approach in vulvar cancer.^{15,16}
- Candidates for SLN biopsy include patients with negative clinical groin examination and imaging, a primary unifocal vulvar tumor size of <4 centimeters, and no previous vulvar surgery that may have impacted lymphatic flow to the inguinal region.^{16,18,19}
- If SLN biopsy is considered, it ideally should be performed by a high-volume SLN surgeon, as high-volume surgeons exhibit improved SLN detection rates.¹⁶
- Increased sensitivity of SLN detection is observed when both radiocolloid and dye are used.^{15,16,17} The radiocolloid most commonly injected into the vulvar tumors is technetium-99m sulfur colloid. It is most commonly injected 2–4 hours prior to the vulvectomy and lymphadenectomy procedure. A preoperative lymphoscintigraphy may be performed to aid in anatomically locating the sentinel node. The dye most commonly used is Isosulfan Blue 1%. Approximately 3–4 cc of dye is injected peri-tumorally using a four-point injection technique at 2, 5, 7, and 10 o'clock. The dye is injected intradermally in the operating room within 15–30 minutes of initiating the procedure.
- It is recommended that the SLN procedure is performed prior to the excision of the vulvar tumor, so as not to disrupt the lymphatic network between the primary vulvar tumor and the inguinal LN basin. Additionally, the injected blue dye will only transiently localize (ie, for 30–60 minutes) in the first group of nodes that correspond to the primary vulvar tumors.
- Use of a gamma probe to detect the injected radiocolloid within the inguinofemoral region is recommended prior to making the groin incision in order to tailor the location and size of the incision.
- A complete inguinofemoral lymphadenectomy is recommended if an ipsilateral SLN is not detected.
- The management of positive SLNs is currently being evaluated and may include performance of complete inguinofemoral lymphadenectomy and/or administration of adjuvant radiation to the affected groin(s).
- If ipsilateral SLN is positive, the contralateral groin should be evaluated surgically and/or treated with EBRT.

Note: All recommendations are category 2A unless otherwise indicated.

Clinical Trials: NCCN believes that the best management of any patient with cancer is in a clinical trial. Participation in clinical trials is especially encouraged.

[Continued](#)



NCCN Guidelines Version 1.2018

Vulvar Cancer (Squamous Cell Carcinoma)

PRINCIPLES OF SURGERY: REFERENCES

- ¹Rouzier R1, Haddad B, Plantier F, et al. Local relapse in patients treated for squamous cell vulvar carcinoma: incidence and prognostic value. *Obstet Gynecol* 2002;100:1159-1167.
- ²Heaps JM, Fu YS, Montz FJ, et al. Surgical-pathologic variables predictive of local recurrence in squamous cell carcinoma of the vulva 1990;38:309-314.
- ³de Hullu JA, Hollema H, Lilkema S, et al. Vulvar carcinoma. The price of less radical surgery. *Cancer* 2002;95:2331-2338.
- ⁴Faul CM, Mirmow D, Huang Q et al. Adjuvant radiation for vulvar carcinoma. Improved local control. *Int J Radiat Oncol Biol Phys* 1997;38:381-389.
- ⁵van den Einden LC, Massuger LF, Jonkman JK, et al. An alternative way to measure the depth of invasion of vulvar squamous cell carcinoma in relation to prognosis. *Mod Pathol* 2015;28:295-302.
- ⁶Pecorelli S. Revised FIGO Staging of the Vulva, Cervix and Endometrium. *Int J Gynecol Oncol* 2009;105:103-104.
- ⁷Vulva: In American Joint Committee on Cancer Staging Manual, 7th, Edge SB, Byrd DR, Compton CC, et al Eds. Springer, New York 2010. p. 379
- ⁸Burger MP, Holema H, Emanuels AG, et al. The importance of groin node status to survival of T1 and T2 vulvar carcinoma patients. *Gynecol Oncol* 1995;57:327-334.
- ⁹DiSaia P, Creasman WT, Rich WM. An alternate approach to early cancer of the vulva. *Am J Obstet Gynecol* 1979; 133:825-832.
- ¹⁰De Hullu JA, Holema H, Lolkema S, et al. Vulvar carcinoma. The price of less radical surgery. *Cancer* 2002; 95:2331-2338.
- ¹¹Stehman FB, Look KY. Carcinoma of the vulva. *Obstet Gynecol* 2006; 107:719-733.
- ¹²Gonzalez-Bosquet J, Magrina JF, Magtibay P, et al. Patterns of inguinal groin node metastases in squamous cell carcinoma of the vulva. *Gynecol Oncol* 2007;105:742-746.
- ¹³Moore DH, Koh WJ, et al. A phase II trial of radiation therapy and weekly cisplatin chemotherapy for the treatment of locally advanced squamous cell carcinoma of the vulva. *Gynecol Oncol* 2012;124:529-533.
- ¹⁴DiSaia P, Creasman WT, Rich WM. An alternate approach to early cancer of the vulva. *Am J Obstet Gynecol* 1979;133:825-832.
- ¹⁵Van der Zee, Oonk MH, De Hullu JA, et al. Sentinel lymph node dissection is safe in the treatment of early-stage vulvar carcinoma. *J Clin Oncol* 2008; 26:884-889.
- ¹⁶Levenback CF, Ali S, Coleman R, et al. Lymphatic mapping and sentinel lymph node biopsy in women with squamous cell carcinoma of the vulva: a gynecologic oncology group study. *J Clin Oncol* 2012;30:3786-791.
- ¹⁷Oonk MH, van Hemel BM, Hollema H, et al., Size of sentinel-node metastasis and chances of non-sentinel-node involvement and survival in early stage vulvar cancer: results from GROINSS-V, a multicentre observational study. *Lancet Oncol* 2010;11:646-652.
- ¹⁸Covens A, Vella ET, Kennedy EB, Reade CJ, Jimenez W, Le T. Sentinel lymph node biopsy in vulvar cancer: Systematic review, meta-analysis and guideline recommendations. *Gynecol Oncol* 2015;137:351-361.
- ¹⁹Te Grootenhuis NC et al. Sentinel nodes in vulvar cancer: Long-term follow-up of the GROningen International Study on Sentinel nodes in Vulvar cancer (GROINSS-V) I. *Gynecol Oncol* 2016 Jan;140:8-14.

Note: All recommendations are category 2A unless otherwise indicated.

Clinical Trials: NCCN believes that the best management of any patient with cancer is in a clinical trial. Participation in clinical trials is especially encouraged.



NCCN Guidelines Version 1.2018

Vulvar Cancer (Squamous Cell Carcinoma)

PRINCIPLES OF RADIATION THERAPY

General Principles

- RT is often used in the management of patients with vulvar cancer as adjuvant therapy following initial surgery, as part of primary therapy in locally advanced disease, or for secondary therapy/palliation in recurrent/metastatic disease.
- Radiation technique and doses are important to maximize tumor control while limiting adjacent normal tissue toxicity.
- Tumor-directed RT refers to RT directed at sites of known or suspected tumor involvement. In general, tumor-directed external beam RT (EBRT) is directed to the vulva and/or inguinofemoral, external, and internal iliac nodal regions. Brachytherapy can sometimes be used as a boost to anatomically amenable primary tumors. Careful attention should be taken to ensure adequate tumor coverage by combining clinical examination, imaging findings, and appropriate nodal volumes at risk to define the target volume. For example invasion into the anus above the pectinate line would necessitate coverage of the perirectal nodes.^{1,2}
- The target tissues should be treated once daily, 5 days per week. Breaks from treatment should be minimized. Adequate dosing is crucial and can be accomplished with either 3D conformal approaches or intensity-modulated radiation therapy (IMRT) as long as care is given to assure adequate dosing and coverage of tissues at risk for tumor involvement.^{1,3} Doses range from 45–50.4 Gy in 25–28 fractions (1.8 Gy fractions) for adjuvant therapy to 59.4–64.8 Gy in 33–36 total fractions (1.8 Gy fractions) for unresectable disease. In select cases, large nodes may be boosted to a total dose of approximately 70 Gy.
- Ensure coverage of gross tumor burden with margin. In highly selected cases where only a superficial vulvar target is to be treated, an enface electron beam may be used.
- Historically a widely disparate range of approaches has been described. In an attempt to better standardize RT use and techniques, a recent international survey, with consequent recommendations, has been reported.⁴
- Acute effects during RT (eg, diarrhea, bladder irritation, fatigue, mucocutaneous reaction) are expected to some degree in most patients, and can be further accentuated by concurrent chemotherapy. These toxicities should be aggressively managed (eg, local skin care, symptomatic medications), and treatment breaks should be avoided or minimized. Many patients may develop an overgrowth of *Candida albicans* and treatment with oral and local anti-fungal agents will markedly reduce skin reaction. If a bacterial infection develops, prompt recognition and appropriate treatment is essential. These acute effects generally resolve several weeks after completion of radiation.
- Postoperative adjuvant treatment should be initiated as soon as adequate healing is achieved, preferably within 6–8 wks.

Note: All recommendations are category 2A unless otherwise indicated.

Clinical Trials: NCCN believes that the best management of any patient with cancer is in a clinical trial. Participation in clinical trials is especially encouraged.

[Continued](#)



NCCN Guidelines Version 1.2018

Vulvar Cancer (Squamous Cell Carcinoma)

PRINCIPLES OF RADIATION THERAPY

3D Conformal/Anterior-Posterior/Posterior-Anterior (AP/PA) Fields

- The target is best defined by both physical examination and CT-based treatment planning; contouring of the target structures is recommended. When an AP/PA technique is primarily used, often wide AP and narrower PA fields are used with electrons supplementing the dose to the inguinal region if the depth of the inguinal nodes allow for electron coverage. More conformal techniques such as three- or four-field approaches may allow for greater sparing of bowel and/or bladder, depending on tumor extent and patient anatomy. CT or MRI planning, with possible image fusion technology, should be used to assure adequate dosing and coverage with contouring of the primary, and the inguinofemoral and iliac nodes. Radio-opaque markers should be placed on key landmarks at the time of simulation to assist in definition of the primary target volume.
- The superior field border should be no lower than the bottom of the sacroiliac joints or higher than the L4/L5 junction unless pelvic nodes are involved. If pelvic nodes are involved, the upper border can be raised to 5 cm above the most cephalad-positive node. The superior border should extend as a horizontal line to cover the inguinofemoral nodes at the level of the anterior-inferior iliac spine. The lateral border will be a vertical line drawn from the anterior-inferior iliac spine. To adequately cover the inguinal nodes the inferio-lateral inguinal nodal border is parallel to the inguinal crease and inferior enough to encompass the inguinofemoral nodal bed to the intertrochanteric line of the femur or 1.5–2 cm distal to the saphenofemoral junction. The inferior vulvar border will be lower and should be at least 2 cm below the most distal part of the vulva. Care should be taken to spare the femoral heads and necks.
- Bolus should be used to ensure adequate dosing to superficial target volume both at the primary site and when lymph nodes are just below the skin surface.

Note: All recommendations are category 2A unless otherwise indicated.

Clinical Trials: NCCN believes that the best management of any patient with cancer is in a clinical trial. Participation in clinical trials is especially encouraged.

[Continued](#)



NCCN Guidelines Version 1.2018

Vulvar Cancer (Squamous Cell Carcinoma)

PRINCIPLES OF RADIATION THERAPY

Intensity-Modulated Radiation Therapy (IMRT)

- The vulvar and nodal targets should be contoured on the planning CT. Any gross vulvar disease should be contoured as a gross tumor volume (GTV) and include any visible and/or palpable extension. The vulvar clinical target volume (CTV) target is defined as the GTV or tumor bed plus the adjacent skin, mucosa, and subcutaneous tissue of the vulva excluding bony tissue. A wire placed clinically to define the vulvar skin borders and the GTV during CT simulation is essential. In addition, a marker on the anus, urethra, clitoris, and the wiring of any scars will aid in planning.
- To ensure adequate distal margin on the vulvar target volume, a “false structure” or bolus should be placed over the vulva for treatment planning purposes. Doses to the target areas should be confirmed using thermoluminescent dosimeter (TLD) at first treatment.
- Symmetrical geometric expansions on the vessels should NOT be used for the inguinofemoral nodes. The inguinofemoral nodal CTV will extend laterally from the inguinofemoral vessels to the medial border of the sartorius and rectus femoris muscles, posteriorly to the anterior vastus medialis muscle, and medially to the pectineus muscle or 2.5–3 cm medially from the vessels. Anteriorly the volume should extend to the anterior border of the sartorius muscle (the most anterior muscle on the lateral inguinofemoral border). The caudal extent of the inguinofemoral nodal basin is the top of the lesser trochanter of the femur.²
- The pelvic nodal CTV is the vasculature of the bilateral external iliac, obturator, and internal iliac nodal regions with a minimum of 7 mm of symmetrical expansion excluding bone and muscle.
- The groin CTV volume will not extend outside the skin and should be trimmed by 3 mm in the absence of skin involvement (with skin involvement, the CTV should extend to the skin with bolus material applied during treatment). Planned treatment volume (PTV) expansion is then 7–10 mm.
- Image-guided IMRT is an essential component of treatment (to account for vulva edema or marked tumor regression).
- Planning should be taken with care to respect normal tissue tolerances such as rectum, bladder, small bowel, and femoral head and neck.⁵
- Bolus should be used to ensure adequate dosing to superficial target volume both at the primary site and when lymph nodes are just below the skin surface.

Note: All recommendations are category 2A unless otherwise indicated.

Clinical Trials: NCCN believes that the best management of any patient with cancer is in a clinical trial. Participation in clinical trials is especially encouraged.

[Continued](#)



NCCN Guidelines Version 1.2018

Vulvar Cancer (Squamous Cell Carcinoma)

PRINCIPLES OF RADIATION THERAPY (REFERENCES)

- ¹Beriwal S, Shukla G, Shinde A, et al. Preoperative intensity modulated radiation therapy and chemotherapy for locally advanced vulvar carcinoma: analysis of pattern of relapse. *Int J Radiat Oncol Biol Phys* 2013;85:1269-1274.
- ²Kim CH, Olson AC, Kim H, et al. Contouring inguinal and femoral nodes; how much margin is needed around the vessels? *Pract Radiat Oncol* 2012;2:274-278.
- ³Moore DH, Ali S, Koh WJ, et al. A phase II trial of radiation therapy and weekly cisplatin chemotherapy for the treatment of locally-advanced squamous cell carcinoma of the vulva: a gynecologic oncology group study. *Gynecol Oncol* 2012;124:529-533.
- ⁴Gaffney DK, King B, Viswanathan AN, et al. Consensus recommendations for radiation therapy contouring and treatment of vulvar carcinoma. *Int J Radiat Oncol Biol Phys* 2016; 95:1191-1200.
- ⁵Kachnic LA, Winter K, Myerson RJ, Goodyear MD, Willins J, Esthappen J, Haddock MG, Rotman M, Parikh PJ, Safran H, Willett CG. RTOG 0529: a phase 2 evaluation of dose-painted intensity modulated radiation therapy in combination with 5-fluorouracil and mitomycin-C for the reduction of acute morbidity in carcinoma of the anal canal. *Int J Radiat Oncol Biol Phys* 2013;86:27-33.

Note: All recommendations are category 2A unless otherwise indicated.

Clinical Trials: NCCN believes that the best management of any patient with cancer is in a clinical trial. Participation in clinical trials is especially encouraged.



NCCN Guidelines Version 1.2018

Vulvar Cancer (Squamous Cell Carcinoma)

SYSTEMIC THERAPY¹

Chemoradiation

- Cisplatin
- Fluorouracil (5-FU) and cisplatin
- 5-FU and mitomycin-C²

Chemotherapy for Advanced, Recurrent/Metastatic Disease

- Cisplatin
- Carboplatin
- Cisplatin/vinorelbine
- Cisplatin/paclitaxel
- Carboplatin/paclitaxel
- Paclitaxel
- Erlotinib (category 2B)³
- Cisplatin/gemcitabine (category 2B)
- Pembrolizumab
(second-line therapy for MSI-H/dMMR tumors)
(category 2B)

¹Reade CJ, Eiriksson LR, Mackay H. Systemic chemotherapy in squamous cell carcinoma of the vulva: Current status and future directions. *Gynecol Oncol* 2014;132:780-789.

²Anal cancer literature supports the use of mitomycin-based regimens based on high-quality evidence. Chin JY, Hong TS, Ryan DP. Mitomycin in anal cancer: still the standard of care. *J Clin Oncol* 2012;30:4297.

³Horowitz NS, Olawaiye AB, Borger DR, et al. Phase II trial of erlotinib in women with squamous cell carcinoma of the vulva. *Gynecol Oncol* 2012;127:141-146.

Note: All recommendations are category 2A unless otherwise indicated.

Clinical Trials: NCCN believes that the best management of any patient with cancer is in a clinical trial. Participation in clinical trials is especially encouraged.



NCCN Guidelines Version 1.2018 Staging Vulvar Cancer (Squamous Cell Carcinoma)

Staging-Vulvar Cancer

Table 1

AJCC Tumor-Node-Metastases (TNM) and International Federation of Gynecology and Obstetrics (FIGO)
Surgical Staging Systems for Carcinoma of the Vulva

T Category	FIGO Stage	T Criteria
TX		Primary tumor cannot be assessed
T0		No evidence of primary tumor
T1	I	Tumor confined to the vulva and/or perineum. Multifocal lesions should be designated as such. The largest lesion or the lesion with the greatest depth of invasion will be the target lesion identified to address the highest pT stage. Depth of invasion is defined as the measurement of the tumor from the epithelial–stromal junction of the adjacent most superficial dermal papilla to the deepest point of invasion.
T1a	IA	Lesions 2 cm or less, confined to the vulva and/or perineum, and with stromal invasion of 1.0 mm or less
T1b	IB	Lesions more than 2 cm, or any size with stromal invasion of more than 1.0 mm, confined to the vulva and/or perineum
T2	II	Tumor of any size with extension to adjacent perineal structures (lower/distal third of the urethra, lower/distal third of the vagina, anal involvement)
T3	IVA	Tumor of any size with extension to any of the following—upper/proximal two thirds of the urethra, upper/proximal two thirds of the vagina, bladder mucosa, or rectal mucosa—or fixed to pelvic bone

The AJCC 8th Edition Cancer Staging System will be implemented on January 1, 2018. For the AJCC 7th Edition Staging Manual, visit www.springer.com.

Used with permission of the American Joint Committee on Cancer (AJCC), Chicago, Illinois. The original and primary source for this information is the AJCC Cancer Staging Manual, Eighth Edition (2016) published by Springer Science+Business Media. (For complete information and data supporting the staging tables, visit www.springer.com.) Any citation or quotation of this material must be credited to the AJCC as its primary source. The inclusion of this information herein does not authorize any reuse or further distribution without the expressed, written permission of Springer SBM, on behalf of the AJCC.

Reprinted from: Pecorelli S. Revised FIGO staging for carcinoma of the vulva, cervix and endometrium. FIGO Committee on Gynecologic Oncology. Int J Gynaecol Obstet 2009;105:103-104. Copyright 2009, with permission from International Federation of Gynecology and Obstetrics.



NCCN Guidelines Version 1.2018 Staging Vulvar Cancer (Squamous Cell Carcinoma)

Staging-Vulvar Cancer

Table 1 continued

Definition of Regional Lymph Node (N)

N Category	FIGO Stage	N Criteria
NX		Regional lymph nodes cannot be assessed
N0		No regional lymph node metastasis
N0(i+)		Isolated tumor cells in regional lymph node(s) no greater than 0.2 mm
N1	III	Regional lymph node metastasis with one or two lymph node metastases each less than 5 mm, or one lymph node metastasis greater than or equal to 5 mm
N1a*	IIIA	One or two lymph node metastases each less than 5 mm
N1b	IIIA	One lymph node metastasis greater than or equal to 5 mm
N2		Regional lymph node metastasis with three or more lymph node metastases each less than 5 mm, or two or more lymph node metastases greater than or equal to 5 mm, or lymph node(s) with extranodal extension
N2a*	IIIB	Three or more lymph node metastases each less than 5 mm
N2b	IIIB	Two or more lymph node metastases greater than or equal to 5 mm
N2c	IIIC	Lymph node(s) with extranodal extension
N3	IVA	Fixed or ulcerated regional lymph node metastasis
*Includes micrometastasis, N1mi and N2mi. Note: The site, size, and laterality of lymph node metastases should be recorded.		

Definition of Metastasis (M)

M Category	FIGO Stage	M Criteria
M0		No distant metastasis (no pathological M0; use clinical M to complete stage group)
M1	IVB	Distant metastasis (including pelvic lymph node metastasis)

Histologic Grade (G)

G	G Definition
GX	Grade cannot be assessed
G1	Well differentiated
G2	Moderately differentiated
G3	Poorly differentiated or undifferentiated

The AJCC 8th Edition Cancer Staging System will be implemented on January 1, 2018. For the AJCC 7th Edition Staging Manual, visit www.springer.com.

Used with permission of the American Joint Committee on Cancer (AJCC), Chicago, Illinois. The original and primary source for this information is the AJCC Cancer Staging Manual, Eighth Edition (2016) published by Springer Science+Business Media. (For complete information and data supporting the staging tables, visit www.springer.com.) Any citation or quotation of this material must be credited to the AJCC as its primary source. The inclusion of this information herein does not authorize any reuse or further distribution without the expressed, written permission of Springer SBM, on behalf of the AJCC.

Reprinted from: Pecorelli S. Revised FIGO staging for carcinoma of the vulva, cervix and endometrium. FIGO Committee on Gynecologic Oncology. Int J Gynaecol Obstet 2009;105:103-104. Copyright 2009, with permission from International Federation of Gynecology and Obstetrics.

NCCN Guidelines Version 1.2018

Vulvar Cancer (Squamous Cell Carcinoma)

Discussion

This discussion is being updated to correspond with the newly updated algorithm. Last updated 10/04/16

NCCN Categories of Evidence and Consensus

Category 1: Based upon high-level evidence, there is uniform NCCN consensus that the intervention is appropriate.

Category 2A: Based upon lower-level evidence, there is uniform NCCN consensus that the intervention is appropriate.

Category 2B: Based upon lower-level evidence, there is NCCN consensus that the intervention is appropriate.

Category 3: Based upon any level of evidence, there is major NCCN disagreement that the intervention is appropriate.

All recommendations are category 2A unless otherwise noted.

Table of Contents

Overview	MS-2
Literature Search Criteria and Guidelines Update Methodology	MS-2
Diagnosis and Workup.....	MS-3
Prognostic Factors.....	MS-4
Surgical Staging	MS-4
Primary Tumor Resection	MS-4
Lymph Node Evaluation.....	MS-5
Panel Recommendations.....	MS-6

Primary Treatment..... MS-7

Early-Stage Disease	MS-7
Panel Recommendations	MS-7
Locally Advanced Disease	MS-7
Chemoradiation	MS-8
Panel Recommendations	MS-9
Metastasis Beyond the Pelvis	MS-9
Panel Recommendations	MS-9

Adjuvant Therapy

Adjuvant RT and Chemoradiation	MS-9
Panel Recommendations	MS-11

Surveillance..... MS-11

Treatment for Recurrent Disease	MS-12
Panel Recommendations	MS-13
Vulva-Confined Recurrence	MS-13
Nodal Recurrence or Distant Metastasis	MS-13

Systemic Therapy for Recurrent/Metastatic Disease..... MS-13

References..... MS-15

NCCN Guidelines Version 1.2018

Vulvar Cancer (Squamous Cell Carcinoma)

Overview

In 2016, an estimated 5950 women will be diagnosed with vulvar cancer, and 1110 are expected to die from the disease.¹ Vulvar cancer accounts for 4% of gynecologic malignancies. Based on data from the SEER database, 5-year survival rates range from 86% for localized disease (stages I/II), to 57% for regional or locally advanced disease (stages III/IVA), and finally to 17% for patients with distant metastasis (stage IVB).² Studies of the SEER database and the National Cancer Database have shown that treatment approaches/modalities vary considerably with sociodemographic factors such as race/ethnicity, age, and non-private insurance, particularly for individuals with advanced disease.^{3,4}

Ninety percent of vulvar cancers are of squamous cell carcinoma (SCC) histology.⁵ Risk factors for the development of vulvar neoplasia include increasing age, infection with human papillomavirus (HPV), cigarette smoking, inflammatory conditions affecting the vulva, and immunodeficiency. Most vulvar neoplasias are diagnosed at early stages.⁶ Although vulvar SCC is the most common type of vulvar cancer, rarer histologies exist. These include melanoma, extramammary Paget's disease, Bartholin gland adenocarcinoma, verrucous carcinoma, basal cell carcinoma, and sarcoma.⁷

The International Society for the Study of Vulvovaginal Disease (ISVVD) has revised the terminology used to characterize vulvar lesions in recent years. In 2004, vulvar intraepithelial neoplasia (VIN) terminology was refined to include 2 types of lesions, usual-type VIN and differentiated VIN.⁸ Usual-type VIN was linked to persistent infection with carcinogenic strains of HPV, while differentiated VIN was commonly associated with vulvar dermatologic conditions such as lichen sclerosus. In 2015, the ISVVD updated the description to 3

classes of vulvar lesions: 1) low-grade squamous intraepithelial lesion (LSIL) due to flat condyloma or HPV effect; 2) high-grade squamous intraepithelial lesions (HSIL, formerly considered usual-type VIN); and 3) differentiated VIN.⁹

Estimates of the percentage of vulvar cancers attributable to HPV infection range from conservative estimates of 30% to up to 69%.¹⁰⁻¹² However, HPV infection is detected in 80% to 90% of HSIL. Historically, VIN has been diagnosed in younger women (median age 45–50 years) while vulvar cancers are diagnosed in older women (median age 65–70 years).^{13,14} Because a large majority of HPV-related vulvar cancers are caused by the HPV-16 and HPV-18 strains, vaccination with currently available HPV vaccines may reduce the burden of HPV-related vulvar cancers in the future.^{10,13}

By definition, the NCCN Guidelines cannot incorporate all possible clinical variations and are not intended to replace good clinical judgment or individualization of treatments. “Many exceptions to the rule” were discussed among the members of the panel during the process of developing these guidelines. Recommendations in the NCCN Guidelines are category 2A unless otherwise noted.

Literature Search Criteria and Guidelines Update Methodology

Prior to the creation of this version of the NCCN Guidelines® for Vulvar Cancer, an electronic search of the PubMed database was performed to obtain key literature in cervical cancer published between 04/01/2015 and 04/01/2016, using the following search terms: vulvar cancer or carcinoma of the vulva. The PubMed database was chosen as it remains the most widely used resource for medical literature and indexes only peer-reviewed biomedical literature. The search results



NCCN Guidelines Version 1.2018

Vulvar Cancer (Squamous Cell Carcinoma)

were narrowed by selecting studies in humans published in English. Results were confined to the following article types: Clinical Trial; Meta-Analysis; Observational Studies; Practice Guideline; Randomized Controlled Trial; Systematic Reviews; and Validation Studies.

The PubMed search resulted in 64 citations and their potential relevance was examined. The data from key PubMed articles as well as articles from additional sources deemed as relevant to these guidelines and discussed by the panel have been included in this version of the Discussion section (eg, e-publications ahead of print, meeting abstracts). Recommendations for which high-level evidence is lacking are based on the panel's review of lower-level evidence and expert opinion.

The complete details of the Development and Update of the NCCN Guidelines are available at www.NCCN.org.

Diagnosis and Workup

Currently, these guidelines focus on the diagnosis, evaluation, and treatment of vulvar SCC. At this time, the guidelines do not address the evaluation and management of rare, non-SCC histologies. For the purposes of this discussion, vulvar SCC will be generally referred to as “vulvar cancer.”

These guidelines utilize the FIGO (International Federation of Gynecology and Obstetrics) and American Joint Committee on Cancer TNM staging systems, which closely align for the staging of vulvar cancer. The FIGO system was updated in 2009;^{15,16} the 8th edition of the AJCC Cancer Staging Manual was released in 2016.¹⁷ In the updated FIGO system, major changes include the combination of the former stage I and II, subclassification based on the number and size of

involved lymph nodes, and shifting away from the focus on bilateral lymph node involvement.¹⁵ The impact of this revised classification system has been examined.¹⁸⁻²⁰

The presentation of vulvar cancer can be widely varied. The majority of vulvar cancers are located in the labia majora. Other possible sites include the labia minora, clitoris, mons, or perineum. In patients with HPV-negative tumors, vulvar cancer often presents as a single mass or ulcer on the labia majora or minora. In HPV-positive tumors, multifocal lesions and concurrent cervical neoplasia are more common.^{13,14,21} Although many cases may be asymptomatic, pruritus and pain/irritation is a common symptom; vulvar bleeding or discharge may also occur. A majority of patients present with early-stage (ie, localized) disease.²

Diagnosis is made through biopsy of all suspicious areas followed by pathologic review. The College of American Pathologists (CAP) protocol for vulvar carcinoma is a useful guide (<http://www.cap.org/ShowProperty?nodePath=/UCMCon/Contribution%20Folders/WebContent/pdf/cp-vulva-16protocol-3200.pdf>). This CAP protocol was revised in January 2016 and reflects recent updates in the AJCC/FIGO staging.

Workup includes history and physical examination, complete blood count (CBC), and liver and renal function tests. In addition to vulva examination, evaluation of the vagina and cervix, including cytologic smears, should be emphasized due to the multifocal nature of squamous cell intraepithelial neoplasia. CT, PET/CT, and MRI may be used to delineate the extent of tumor and/or for treatment planning.²²⁻²⁶ Examination-under-anesthesia (EUA) cystoscopy or proctoscopy are should be considered as indicated. Appropriate patients should receive smoking cessation counseling and HPV testing.

NCCN Guidelines Version 1.2018

Vulvar Cancer (Squamous Cell Carcinoma)

Prognostic Factors

Historically, en bloc vulvectomy with wide margins was combined with complete inguinofemoral lymphadenectomy to treat vulvar SCC. While effective in promoting survival, this approach was associated with serious short- and long-term morbidity (eg, wound complications, lymphedema, decreased sexual function, adverse impacts on body image). The emergence of data on important prognostic factors in vulvar cancer informed the evolution of surgical staging and primary treatment.²¹ Based on a retrospective review of 586 patients enrolled in Gynecologic Oncology Group (GOG) trials through 1984, independent predictors of survival included the presence and number of involved lymph nodes, as well as primary tumor size.²⁷ Lymph node metastasis is considered the most important prognostic factor and determinant of treatment in vulvar cancer,^{28,29} and extracapsular extension has been linked to poorer prognosis.³⁰⁻³³ Additional factors that have been shown to be predictive of recurrence and/or survival include depth of invasion, tumor thickness, and presence of lymphovascular space invasion (LVSI).^{13,27,34-37}

These important prognostic data have guided the shift towards more conservative primary tumor resection and regional lymph node management for early-stage disease.³⁸ The preferred surgical approach evolved towards vulvar conservation with separate incisions for lymph node dissection in patients who were clinically node negative.^{21,39} Current surgical approaches involve tailored primary tumor resection and lymph node evaluation based on individual patient characteristics.^{40,41} Data suggest that survival is not negatively impacted by less radical surgical approaches for early-stage cancers.⁴¹

Surgical Staging

The AJCC and FIGO systems stage vulvar cancer according to extent of primary tumor (T), lymph node status (N), and distant metastasis (M). Clinical staging alone provides inadequate evaluation of lymph node involvement. Because lymph node metastasis is a primary prognostic factor in vulvar cancer survival,^{28,41} these systems use a hybrid surgical and clinical/pathologic approach for more accurate evaluation of nodal status. Complete staging using the existing system requires primary tumor resection and inguinofemoral lymphadenectomy. However, common practice has increasingly included the use of sentinel lymph node (SLN) biopsy in lieu of complete lymph node dissection, as well as diagnostic imaging to determine extent of disease.^{42,43}

Primary Tumor Resection

Depending on the size and extent of the primary tumor, radical local excision or modified radical vulvectomy may be required. No prospective data are available to compare outcomes between these resection techniques; however, retrospective data suggest no difference in recurrence and/or survival.⁴⁴⁻⁴⁶ Both surgical approaches involve resection of approximately a 1- to 2-cm margin of grossly normal tissue and to the deep fascia or a minimum of 1 cm of tissue depth.

Vulvar cancer is associated with significant risk of local recurrence, and data demonstrate tumor margin status to be a significant prognostic factor.^{34,37,47} A recent review identified 4-year recurrence-free rates of 82%, 63%, and 37% for patients with negative, close, and positive margins, respectively ($P = .005$). The highest risk of recurrence was associated with margins ≤ 5 mm.⁴⁸ The goal of primary tumor resection is complete removal with 1- to 2-cm margins. In the setting of close (< 8

NCCN Guidelines Version 1.2018

Vulvar Cancer (Squamous Cell Carcinoma)

mm) or positive tumor margins, re-resection to obtain adequate margins or adjuvant local radiation therapy (RT) are options.^{34,49}

The risk-benefit ratio and morbidity of each approach must be weighed and individualized for each patient. Evidence supports improved recurrence rates and survival with re-resection or adjuvant EBRT to the primary site.⁵⁰ However, for close or positive margins involving the urethra, anus, or vagina, re-resection may incur significant morbidity and negatively impact patient quality of life. Re-resection may also be inappropriate for patients with close or positive margins who have inguinal node involvement requiring adjuvant treatment with EBRT ± chemotherapy.

Lymph Node Evaluation

Because lymph node status is the most important determinant of survival in vulvar cancer, careful evaluation and determination of nodal status is paramount. Lymph node resection is performed through a separate incision from the primary tumor and may entail unilateral or bilateral inguofemoral lymphadenectomy, or SLN biopsy in select cases. Inguofemoral lymphadenectomy involves removal of superficial inguinal and deep femoral lymph nodes (ie, superficial to the inguinal ligament, within the proximal femoral triangle, and deep to the cribriform fascia). Further emphasizing the importance of adequate inguofemoral lymph node (IFLN) evaluation and treatment at initial presentation, it has been widely reported that subsequent groin relapses are rarely amenable to successful secondary treatment.

Lymph node dissection in patients with clinically negative groin nodes is informed by the size and location of the primary tumor. Because the risk of lymph node metastasis is less than 1% in patients with stage IA disease,⁴⁰ lymphadenectomy is not required for those with T1A and N0

tumors. However, inguofemoral lymphadenectomy is recommended for patients with stage IB/II disease because the risk of nodal metastasis is estimated at greater than 8% for stage IB tumors.⁴⁰ Lymphadenectomy for stage III/IV disease is individualized, and integrated with combined modality approaches. For primary vulvar tumors <4 cm in diameter, located at least 2 cm from the vulvar midline, with clinically negative IFLNs, unilateral inguofemoral lymphadenectomy or SLN biopsy are appropriate.^{51,52} However, bilateral lymph node evaluation (full dissection or SLN biopsy, if indicated) is recommended for patients with primary tumors that are within 2 cm of, or crossing, the vulvar midline.⁵²

SLN Biopsy

Reported rates of postoperative morbidity with unilateral or bilateral inguofemoral lymphadenectomy are high. An estimated 20% to 40% of patients have wound complications and 30% to 70% of patients experience lymphedema.^{53,54} In a summary of 12 retrospective studies of patients with negative groin lymphadenectomy, groin recurrence rates varied from 0% to 5.8%,⁵⁵ suggesting the potential to safely avoid completion lymphadenectomy in patients with negative sentinel lymph nodes. To investigate this approach, several prospective multicenter trials have evaluated the feasibility, safety, validity, and risk of groin recurrences with SLN biopsy in early vulvar cancer.

The safety of SLN biopsy was examined in a multicenter observational study of 403 women with primary vulvar tumors <4 cm. Inguofemoral lymphadenectomy was omitted if SLN(s) were negative on ultrastaging. With a median follow-up period of 35 months (24-month minimum), groin recurrences were detected among 6 of 259 patients (2.3%) with a unifocal primary tumor and negative SLN; the 3-year survival rate was

NCCN Guidelines Version 1.2018

Vulvar Cancer (Squamous Cell Carcinoma)

97%. Short- and long-term morbidity was reduced if the SLN only was removed compared with SLN removal followed by full groin dissection.⁵⁵

The GROINSS-V observational study was also performed in this cohort, examining the 135 of 403 patients with positive SLNs (33%).

Investigators examined the relationship between size of sentinel node metastasis and risk of non-sentinel node disease among 115 patients who underwent inguofemoral lymphadenectomy following detection of positive sentinel nodes. Risk of non-SLN involvement increased steadily with the size of SLN metastasis, beginning at 4.2% with detection of isolated tumor cells and increasing to 62.5% with SLN metastases >10 mm. Disease-specific survival (DSS) was worse among those with SLN metastases >2 mm versus ≤2 mm (69.5% vs. 94.4%, $P = .001$).⁵⁶

Patients undergoing SLN biopsy reported less treatment-related morbidity compared with those undergoing IFLN dissection; however, patient-reported quality of life did not differ significantly between the groups.⁵⁷

Long-term follow-up of the GROINSS-V cohort compared outcomes of SLN-positive patients who underwent IFLN dissection with those of SLN-negative patients (no IFLN dissection). At a median follow-up of 105 months, the data revealed a 5- and 10-year recurrence rate of 24.6% and 36.4% for SLN-negative patients, and 33.2% and 46.4% for patients with a positive SLN ($P = .03$). DSS at 10 years was 91% in the SLN-negative group and 65% in the SLN-positive group ($P < .0001$).⁵⁸

In GOG 173,452 women (with vulva-confined primary tumors 2 cm–6 cm, at least 1-mm invasion, and clinically node negative) underwent SLN mapping and biopsy followed by inguofemoral lymphadenectomy. SLNs were identified in 418 women, and 132

women were node positive (including 11 false-negative nodes). SLN biopsy had a sensitivity of 91.7%, negative predictive value of 96.3%, and false-negative predictive value of 3.7% overall (2% for primary tumors <4 cm).⁵⁹ A recent systematic review and meta-analysis of the cumulative data on SLN biopsy revealed a per-groin detection rate of 87% when using dual tracers, and a false-negative rate of 6.4%. When comparing inguofemoral lymphadenectomy, superficial inguofemoral lymphadenectomy, and SLN biopsy, recurrences rates were 1.4%, 6.6%, and 3.4%, respectively.⁶⁰

The ongoing GROINSS-VII/GOG 270 study (NCT01500512) is comparing radiotherapy of the groin to groin node dissection among patients with SLN metastases.

Panel Recommendations

For appropriate individuals, the panel considers SLN mapping and biopsy of the IFLN basin a reasonable alternative approach to decrease postoperative morbidity while maintaining a low of groin recurrences with this surgical approach in vulvar cancer.^{55,56,59}

Candidates for SLN biopsy should have clinically/radiologically negative groin nodes, unifocal primary tumor less than 4 cm, and no history of previous vulvar surgery.^{56,60} Mapping and biopsy should be performed by a high-volume SLN surgeon using dual tracers (ie, radiocolloid and dye) to ensure the best detection rates.^{59,60} The panel recommends complete inguofemoral lymphadenectomy if no ipsilateral SLN is detected. If the ipsilateral SLN is positive, completion lymphadenectomy or treatment of the affected groin may be warranted. Additionally, surgical evaluation or treatment of the contralateral groin is indicated.

NCCN Guidelines Version 1.2018

Vulvar Cancer (Squamous Cell Carcinoma)

Primary Treatment

For the purposes of primary treatment, these guidelines provide treatment recommendations by clinical stage, separating patients into those with early-stage (stage I/II), locally advanced (stage III/IVA), and distant metastatic disease (stage IVB, beyond the pelvis). Patients with early-stage disease include those with T1 or smaller T2 primary tumors; smaller T2 primary tumors are classified as ≤ 4 cm with no/minimal involvement of the urethra, vagina, or anus. Patients with locally advanced disease include those with larger T2 or T3 primary tumors for whom visceral-sparing primary surgery is not indicated. Patients with distant metastatic disease may fall within any “T” or “N” classification, and must have disease beyond the pelvis.

Early-Stage Disease

After careful clinical evaluation and staging, the standard primary treatment of early-stage vulvar SCC is conservative, individualized tumor excision with IFLN evaluation.^{39,45,61-64} Clinicians should strive for primary tumor resection with oncologically appropriate margins of 1 to 2 cm if feasible.^{34,37,47,49} See *Primary Tumor Resection and Lymph Node Evaluation* in this discussion. Although there are no prospective data comparing radical local incision to radical vulvectomy, existing data from retrospective analyses do not demonstrate a difference in recurrence or survival outcomes.^{45,46}

Surgical dissection and RT have been evaluated for treatment of the groin in early-stage disease. Limited data suggest that primary groin radiation results in less morbidity than surgical dissection.⁶⁵ However, surgical treatment of the groin has been associated with lower groin recurrence rates and remains the preferred approach.⁶⁶ Primary

radiation may have some benefit for those unable to undergo surgery.^{67,68}

Panel Recommendations

For T1 tumors with ≤ 1 mm depth of invasion (pT1A), the panel recommends wide local resection or radical local resection; IFLN evaluation is not required due to the low risk of lymph node metastasis in these patients.^{40,62,69-72} Patients should be observed following resection. If surgical pathology reveals greater than 1-mm invasion, additional surgery may be indicated.

In treatment for patients with T1 or smaller T2 tumors with depth of invasion in excess of 1 mm, primary treatment is dictated by tumor location. Patients with lateralized lesions (>1 -mm invasion) located ≥ 2 cm from the vulvar midline should undergo radical local resection or modified radical vulvectomy accompanied by ipsilateral groin node evaluation.^{51,52,69} Groin evaluation can be performed through SLN biopsy or ipsilateral IFLN dissection. Dissection should be performed if no SLN(s) is/are detected. Adjuvant therapy is informed by primary tumor and nodal surgical pathology. Patients with midline vulvar lesions (>1 -mm invasion) should undergo radical local resection or modified radical vulvectomy accompanied by bilateral groin node evaluation consisting of SLN biopsy or ipsilateral IFLN dissection.^{45,52,69} Groin dissection is required on side(s) for which sentinel nodes are not detected. Adjuvant therapy is informed by primary tumor and nodal surgical pathology.

Locally Advanced Disease

Historically, locally advanced vulvar cancers were treated primarily with radical surgeries such as en bloc radical vulvectomy with bilateral inguofemoral lymphadenectomy or pelvic exenteration. These surgeries resulted in some cures, but also led to significant

NCCN Guidelines Version 1.2018

Vulvar Cancer (Squamous Cell Carcinoma)

postoperative complications, loss of function, and reduced quality of life.^{21,73-75} Additionally, complete resection of locally advanced disease may be complicated by tumor fixed to vital organs or vessels, rendering the disease unresectable.⁷⁶ A shift to multimodality treatment was explored to improve organ preservation and reduce surgical treatment morbidity.⁷⁷ Preoperative RT was shown in some earlier studies to result in tumor debulking and reduce the extent of surgery required for locally advanced disease.^{76,78-81} Subsequently, borrowing on experience from advanced cervical and anal cancers, chemotherapy typically has been combined added as a “radiosensitizer” when radiation is delivered in patients with advanced disease.

Chemoradiation

Research directly comparing treatment approaches for locally advanced vulvar cancers is limited. Data from small patient cohorts have shown a generally high response rate to chemoradiation among most patients with stage III/IVA disease, as well as the feasibility of resection for residual disease following chemoradiation. Following chemoradiation, at least partial tumor responses were noted among a wide majority of the patients in these cohorts,⁸²⁻⁸⁶ with several studies revealing complete tumor responses among more than 60% of the cohort.⁸⁷⁻⁹¹ Overall survival (OS) after primary chemoradiation was superior to OS following primary RT in a series of 54 patients with locally advanced disease.⁹²

In the GOG 101 study, preoperative chemoradiation was examined in 73 patients with stage III/IV disease.⁸⁴ The study investigated whether chemoradiation allowed for less radical surgery in patients with T3 tumors and avoidance of pelvic exenteration in patients with T4 tumors. Only 3% of patients (2/71) had residual unresectable disease following chemoradiation, and preservation of urinary and/or gastrointestinal continence was possible in 96% of patients (68/71).

Two prospective studies from the GOG more closely examined the benefits of surgery after chemoradiation for patients with locally advanced disease. GOG 101 examined 46 patients with vulvar SCC and N2/N3 nodal involvement.⁹³ Subsequent surgery was performed on 38 patients with resectable disease after chemoradiation with cisplatin/5-fluorouracil (5-FU). Local control of nodal disease was achieved in 36/37 patients and for the primary tumor in 29/38 patients. More recently, the GOG 205 study examined the feasibility of surgery after chemoradiation with cisplatin in 58 patients with T3/T4 tumors that were initially unresectable by radical vulvectomy.⁹⁴ Complete clinical response was noted in 64% of patients (37/58) with complete pathologic response in 78% (29/34) of patients undergoing surgical biopsy. The high pathologic complete response (PCR) rates have led many to believe that surgery can be avoided in these locally advanced tumors who achieve clinical complete responses.

A 2011 Cochrane database review of the existing randomized controlled trial data on 141 women with locally advanced vulvar SCC revealed no difference in OS when comparing primary surgery to primary or neoadjuvant chemoradiation.⁹⁵ However, the data did not allow for broad conclusions to be drawn regarding treatment-related quality of life and adverse events. An earlier Cochrane database review of 5 non-randomized trials suggested that patients with unresectable primary disease and those requiring exenteration may benefit from neoadjuvant chemoradiation if disease was rendered resectable or requiring less radical surgery.⁹⁶

The combination regimen used for radiosensitization was most commonly cisplatin/5-FU,^{84,85,87,89,90} but also included 5-FU/mitomycin C^{83,86,91} or single-agent therapy.^{88,94} The selection of radiosensitizing

NCCN Guidelines Version 1.2018

Vulvar Cancer (Squamous Cell Carcinoma)

chemotherapy is often based on extrapolation of findings from cervical, anal, or head and neck cancer.

Panel Recommendations

Patients with larger T2 or T3 tumors should undergo radiologic imaging if not previously performed to examine potential nodal involvement. The panel recommends that all patients with locally advanced disease receive EBRT with concurrent chemotherapy. IFLN dissection may be used to assess nodal metastasis to inform RT treatment planning.

If IFLN dissection is not performed, or if positive IFLNs are found upon dissection, EBRT coverage should include primary tumor, groin, and pelvis. If no positive nodes are detected following inguinofemoral lymphadenectomy, EBRT with concurrent chemotherapy should be provided with RT coverage of the primary tumor, with or without selective coverage of groin lymph nodes.

Patients with radiographically positive nodes (including those with pelvis-confined metastases) should be evaluated for IFLN dissection. If groin node dissection is not performed, fine-needle aspiration (FNA) of enlarged lymph nodes can be considered. Patients should receive EBRT and concurrent chemotherapy; EBRT coverage should include the primary tumor, groin, and pelvis. Selective groin/pelvis RT coverage can be considered if dissection reveals no positive lymph nodes.

Agents recommended by the panel for chemoradiation include cisplatin, 5-FU/cisplatin, and 5-FU/mitomycin-C.^{97,98}

Metastasis Beyond the Pelvis

Data on systemic treatments for vulvar SCC with distant metastasis are extremely limited.⁹⁹⁻¹⁰¹ Treatment regimens are often extrapolated from agents that are active against advanced cervical cancer. See the

section on *Systemic Therapy for Recurrent/Metastatic Disease* in this discussion for information about specific regimens.

Panel Recommendations

Primary treatment options for extra-pelvic metastatic disease include EBRT for control of locoregional disease and symptom control, and/or chemotherapy. Best supportive care is also an alternative in this setting. Agents recommended by the panel for treating advanced, recurrent/metastatic disease include cisplatin, carboplatin, paclitaxel (category 2B), and erlotinib (category 2B) as single agents, as well as cisplatin/vinorelbine, cisplatin/paclitaxel, and carboplatin/paclitaxel (category 2B).⁹⁷

Adjuvant Therapy

Due to the rarity of vulvar cancer, especially advanced disease, prospective randomized trials on adjuvant therapy are extremely limited. Much of the common adjuvant treatment approaches have been drawn from studies describing heterogenous, often individualized treatment approaches, or extrapolated from effective adjuvant therapies for cervical and anal cancers.

Adjuvant RT and Chemoradiation

Although it is commonly accepted that lymph node involvement is a critical prognostic factor in vulvar SCC, the optimal patient selection criteria and adjuvant therapy regimens to address nodal disease continue to be determined.¹⁰² As previously emphasized, it is crucial to prevent metachronous groin relapses, as these often prove refractory to secondary management and are often ultimately fatal.

Early randomized trial data on adjuvant RT was published from GOG 37, which enrolled 114 patients with groin node-positive vulvar cancer

NCCN Guidelines Version 1.2018

Vulvar Cancer (Squamous Cell Carcinoma)

after radical vulvectomy and bilateral inguofemoral lymphadenectomy.^{103,104} Patients were randomized to receive pelvic node dissection or adjuvant RT to the groin/pelvis. Two- and 6-year survival was superior in the adjuvant RT group, but the most significant survival benefits were observed among patients with ≥ 2 positive groin nodes or those with fixed ulcerative groin nodes. Long-term follow-up (median = 74 months) revealed higher rates of disease-related death rate for the group receiving pelvic node resection compared with pelvic/groin RT (51% vs. 29%; HR, 0.49; $P = .015$).¹⁰⁴

There are conflicting data on the benefit of adjuvant RT in patients with a single positive lymph node. Some studies in patients with a single positive lymph node have reported no benefit of adjuvant RT in this setting.^{105,106} However, examination of SEER data from 208 patients with stage III, single node–positive vulvar SCC revealed significant improvements in 5-year DSS with the addition of adjuvant RT compared with those receiving no RT.¹⁰⁷ The survival benefit was more pronounced among patients who underwent less extensive lymphadenectomy (≤ 12 nodes excised).

In a case series of 157 patients, DFS at 2 years was 88% in node-negative patients, but 60%, 43%, and 29% in patients with 1, 2, and > 2 positive nodes. The number of involved nodes negatively impacted prognosis in patients receiving no adjuvant RT, but among patients receiving adjuvant RT to the groin/pelvis, the number of metastatic nodes did not harm prognosis.¹⁰⁸

A large multicenter retrospective study reported significant survival benefits in node-positive patients receiving adjuvant RT or chemoradiation (3-year progression-free survival [PFS] of 39.6% vs. 25.9%, $P = .004$; 3-year OS of 57.7% vs. 51.4%, $P = .17$).¹⁰⁶ RT

coverage most commonly included the groin and pelvis \pm coverage of the vulva, with a smaller subset receiving coverage to the groin \pm vulvar coverage. Again, the benefits of adjuvant RT were most clear for patients with ≥ 2 positive lymph nodes.

When adjuvant RT to the lymph nodes is delivered, care should be used to avoid excessive blocking of the central pelvic structures.¹⁰⁹

Recent examination of data from the National Cancer Database supported the addition of chemotherapy to RT in the adjuvant setting. Among 1797 patients with node-positive vulvar cancer, 26.3% received adjuvant chemotherapy in addition to RT after primary surgery. Adjuvant chemotherapy increased survival time and reduced mortality risk (44 months vs. 29.7 months; HR, 0.62; 95% CI, 0.48–0.79; $P < .001$).¹¹⁰ Based on SEER data, outcomes of adjuvant RT were examined in 519 patients aged 66 and older who received primary surgery for node-positive vulvar cancer. Adjuvant RT was associated with improved OS over surgery alone in this cohort of older women (HR, 0.71; 95% CI, 0.57–0.88; $P = .002$) along with a trend towards improved cause-specific survival (HR, 0.79; 95% CI, 0.59–1.05; $P = .11$).¹¹¹ Parameters for delivery of RT were important among this cohort; 3-year OS and CSS were significantly improved in patients who received ≥ 20 fractions (3-year OS: 34% vs. 26%, $P = .008$; 3-year CSS: 48% vs. 37%, $P = .03$).

Research has also examined the role of adjuvant RT to the primary tumor site. Studies have indicated that isolated primary site recurrences may be addressed effectively by subsequent surgery, or that late recurrences may actually represent secondary tumors. The benefit of adjuvant RT to the vulva in patients with close/positive surgical margins has also been investigated.¹¹² Among patients with close/positive

NCCN Guidelines Version 1.2018

Vulvar Cancer (Squamous Cell Carcinoma)

surgical margins at the primary site, 5-year OS was significantly improved by the addition of adjuvant RT to the primary site (67.6% vs. 29%; HR, 0.36; $P = .038$). Patients receiving adjuvant RT for close/positive margins had a similar 5-year OS to those with negative margins. A retrospective study examined the association of RT dose with vulvar recurrence, revealing lower risk of recurrence in patients receiving doses of ≥ 56 Gy compared with those receiving ≤ 50.4 Gy.⁴⁸

Panel Recommendations

For patients with early-stage disease (T1) and a depth of invasion ≤ 1 mm (pT1a), observation is appropriate following primary surgery. For patients with T1b and T2 disease, surgical evaluation of the groin is indicated in addition to primary site surgery. Nodal status is an important determinant of adjuvant therapy recommendations. For patients with a negative SLN or negative IFLNs, observation can be considered.^{55,113-116} Adjuvant therapy is warranted if the SLN or IFLNs contain metastases. Adjuvant therapy for patients with SLN involvement includes: 1) RT (category 1) with or without concurrent chemotherapy; or 2) completion IFLN dissection followed by EBRT with or without concurrent chemotherapy. Adjuvant therapy for patients who have positive IFLNs detected during groin node dissection includes EBRT (category 1) with or without concurrent chemotherapy. Chemoradiation is strongly recommended for patients with 2 or more positive IFLNs or a single IFLN with >2 -mm metastasis.^{103,106}

In addition to nodal status, a number of primary tumor risk factors may influence adjuvant therapy decisions. These include LVSI, close or positive tumor margins, tumor size, depth of invasion, and/or diffuse/spray pattern of invasion. Observation is reasonable in the setting of negative primary tumor margins with no additional risk factors. Treatment of patients with primary tumor margins positive for

noninvasive disease (eg, HSIL) should be individualized. If surgical margins are positive for invasive disease, re-excision should be considered to achieve oncologically appropriate margins. Patients with continued positive margins after re-excision should receive adjuvant EBRT.¹¹² Patients with oncologically appropriate margins following re-excision may be candidates for observation unless additional risk factors warrant adjuvant EBRT. For patients with positive margins for invasive disease who are not candidates for re-excision, adjuvant EBRT should be offered.

For patients with locally advanced disease, adjuvant therapy decisions should be made based on clinical evaluation of treatment response after EBRT with concurrent chemotherapy (potentially preceded by IFLN dissection). These guidelines provide adjuvant therapy recommendations based on whether patients are clinically negative or positive for residual tumor at the primary site and in the groin. Patients with no clinical evidence of residual tumor after EBRT with concurrent chemotherapy should undergo surveillance. Biopsy of the tumor bed can also be considered to confirm PCR. Patients with residual tumor should be considered for resection. In the case of positive margins on resection, providers should consider additional surgery, additional EBRT, and/or systemic therapy, or best supportive care. For unresectable residual disease, providers should consider additional EBRT and/or systemic therapy, or best supportive care.

Surveillance

Most recurrences of vulvar cancer occur within the first year, although recurrences beyond 5 years have been observed in a significant subset of patients.¹¹⁷ Accordingly, long-term follow-up is indicated. Definitive data on an optimal surveillance strategy is lacking.¹¹⁸ However, the



NCCN Guidelines Version 1.2018

Vulvar Cancer (Squamous Cell Carcinoma)

panel concurs with the updated Society of Gynecologic Oncology recommendations for post-treatment surveillance.¹¹⁹

The recommended surveillance is based on the patient's risk for recurrence and personal preferences. History and physical examination is recommended every 3 to 6 months for 2 years, every 6 to 12 months for another 3 to 5 years, and then annually (see *Surveillance* in the NCCN Guidelines for Vulvar Cancer). Patients with high-risk disease can be assessed more frequently (eg, every 3 months for the first 2 years) than patients with low-risk disease (eg, every 6 months).

Annual cervical/vaginal cytology tests can be considered as indicated for detection of lower genital tract dysplasia, although its value in detecting recurrent cancers is limited and the likelihood of detecting asymptomatic recurrence is low. Imaging (ie, chest radiography, CT, PET/CT, MRI) and laboratory testing (ie, CBC, blood urea nitrogen [BUN], creatinine) is recommended as indicated by suspicious examination findings or symptoms of recurrence.

Patient education regarding symptoms suggestive of recurrence or vulvar dystrophy is recommended, as well as periodic self-examination. Patients should also be counseled on healthy lifestyle, obesity, nutrition, exercise, and sexual health (including vaginal dilator use and lubricants/moisturizers). For information on these and other issues related to survivorship (ie, pain/neuropathy, fear of recurrence, and depression), see the NCCN Guidelines for Survivorship. Smoking cessation and abstinence should be encouraged, see the NCCN Guidelines for Smoking Cessation.

Sexual dysfunction and low body image is unfortunately common among women who have undergone vulvectomy and/or RT of the groin/pelvis.^{54,120,121} Patients who received RT for vulvar cancer may

experience vaginal stenosis and dryness and should receive education on important issues regarding sexual health and vaginal health. Providers should inform patients about regular vaginal intercourse and/or vaginal dilator use and on the use of vaginal moisturizers/lubricants (eg, estrogen creams as well as non-hormonal options). Anecdotal evidence suggests that vaginal dilators may be used to prevent or treat vaginal stenosis. Dilator use can start 2 to 4 weeks after RT is completed and can be performed indefinitely (<https://www.mskcc.org/cancer-care/patient-education/improving-your-vaginal-health-after-radiation-therapy>).

If persistent or recurrent disease is suspected, patients should be evaluated using additional imaging studies and biopsy as outlined in the next section.

Treatment for Recurrent Disease

A multicenter case series evaluated the rate and patterns of recurrence among 502 patients, 187 (37%) of who developed a recurrent vulvar SCC. Just over half of recurrences were vulvar (53.4%), followed by inguinal (18.7%), multi-site (14.2%), distant (7.9%), and pelvic (5.7%). Survival rates at 5 years were 60% for vulvar recurrence, 27% for inguinal/pelvic, 15% for distant sites, and 14% for multiple sites.²⁹ While localized vulvar recurrences can be successfully addressed with subsequent surgery, some studies have suggested higher risk of cancer-related death.

Given the rarity of primary vulvar cancer, data for treating recurrences are even scarcer and no clear standard of care exists.¹²² Treatment approach and patient outcomes depend on the site and extent of recurrent disease.^{122,123} Isolated local recurrences can often be treated successfully with radical local excision,^{29,124} and RT with or without

NCCN Guidelines Version 1.2018

Vulvar Cancer (Squamous Cell Carcinoma)

chemotherapy provided some degree of DFS in several studies.^{80,81} A retrospective review of patients with locoregional recurrences were managed with chemoradiation, neoadjuvant chemotherapy, or RT alone. Five-year DFS and OS were around 20%; however, those with single-site recurrence and lesions ≤ 3 cm who received RT dose at or above 64.8 Gy remained disease-free at 5 years.¹²⁵ Conversely, another series noted decline in survival with the presence of nodal metastases, tumors > 3 cm, or high-grade lesions.¹²⁶ For central/large recurrences, pelvic exenteration has been shown to prolong survival when performed on carefully selected patients.^{73,74,127} Regardless of treatment approach, prognosis for nodal recurrences was very poor.^{124,126,128,129}

Panel Recommendations

If recurrence is suspected, the panel recommends workup for metastatic disease with imaging studies. Biopsy can be considered to confirm distant metastasis. Treatment recommendations for recurrent disease are outlined according to site of recurrence and previous therapies received.

Vulva-Confined Recurrence

If recurrence is clinically limited to the vulva with clinically negative nodes, and the patient did not receive prior RT, the panel recommends surgical and RT treatment pathways. Surgical recommendations include radical excision with unilateral or bilateral IFLN dissection if lymphadenectomy was not previously done. Pelvic exenteration can be considered for select cases with a central recurrence. Additional therapy is indicated by margin status and nodal status. Observation is appropriate for negative margins and nodes. In patients with positive margins but no evidence of nodal involvement, options include re-excision or EBRT with or without brachytherapy and/or concurrent

chemotherapy (category 2B for chemotherapy). EBRT with or without chemotherapy is recommended for patients with negative surgical margins but surgically positive IFLNs. In patients with both positive margins and surgically positive IFLNs, the panel recommends EBRT, with or without brachytherapy, concurrent chemotherapy, and/or re-excision as needed/appropriate.

Nonsurgical therapy for recurrence includes EBRT with or without brachytherapy and/or concurrent chemotherapy. Resection can be considered for patients with gross residual tumor. When feasible, resection is also indicated for patients with vulva-confined recurrence who were previously irradiated. After treatment for recurrence, patients should undergo surveillance.

Nodal Recurrence or Distant Metastasis

Chemotherapy, palliative/best supportive care, or clinical trial enrollment is recommended for patients experiencing recurrence who received prior pelvic EBRT, and for patients with multiple positive pelvic nodes or distant metastasis. Resection followed by systemic therapy can be considered for select cases of isolated groin/pelvic recurrence that were previously irradiated.

If recurrence is limited to the groin and no prior RT was given, then consider resection of positive nodes followed by EBRT with or without concurrent chemotherapy. For unresectable nodes, EBRT with or without concurrent chemotherapy is appropriate. All patients should undergo surveillance following treatment for recurrent disease.

Systemic Therapy for Recurrent/Metastatic Disease

No standard chemotherapy regimens exist for treating advanced or recurrent/metastatic disease. Several reports provide anecdotal



NCCN Guidelines Version 1.2018

Vulvar Cancer (Squamous Cell Carcinoma)

evidence for various regimens, at times extrapolating from regimens with known activity in advanced cervical and anal cancers, as well as other SCCs. See the review article by Reade et al for an overview of systemic therapies that have been utilized to treat vulvar SCC.⁹⁷ See *Systemic Therapy* in the algorithm for recommended agents.

Cisplatin is a commonly employed radiosensitizing agent in locally advanced vulvar cancer, and is recommended for single-agent or combination chemotherapy for treatment of metastatic disease.^{76,130}

Cisplatin/vinorelbine was studied in a small case series of patients with recurrent disease, producing a 40% response rate, 10-month PFS, and 19-month OS.¹³¹

Carboplatin (category 2A) is an alternative platinum agent active in metastatic cervical cancer that can be used as a single agent or in combination with paclitaxel (category 2B). A small series in 6 patients with advanced or recurrent/metastatic vulvar cancer noted limited clinical benefit of the combination regimen,⁹⁹ however, it has been included in these guidelines based on data from patients with advanced or recurrent/metastatic cervical cancer.¹³²

Paclitaxel (category 2B) was modestly active in a phase II trial of 31 women with advanced, recurrent/metastatic vulvar cancer, generating a response rate of 14% and PFS of 2.6 months.¹⁰⁰

Erlotinib was studied in a phase II trial that included a cohort of women with metastatic disease. Short-duration responses were observed, with partial responses and stable disease noted in 27.5% and 40% of enrolled patients, respectively.¹⁰¹

Discussion
Update in
progress

References

1. Siegel RL, Miller KD, Jemal A. Cancer statistics, 2016. CA Cancer J Clin 2016;66:7-30. Available at: <http://www.ncbi.nlm.nih.gov/pubmed/26742998>.
2. SEER Cancer Statistics Factsheets: Vulvar Cancer. Bethesda, MD: National Cancer Institute; Available at: <http://seer.cancer.gov/statfacts/html/vulva.html>. Accessed April 22, 2016.
3. Tergas AI, Tseng JH, Bristow RE. Impact of race and ethnicity on treatment and survival of women with vulvar cancer in the United States. Gynecol Oncol 2013;129:154-158. Available at: <http://www.ncbi.nlm.nih.gov/pubmed/23274562>.
4. Chase DM, Lin CC, Craig CD, et al. Disparities in vulvar cancer reported by the National Cancer Database: influence of sociodemographic factors. Obstet Gynecol 2015;126:792-802. Available at: <http://www.ncbi.nlm.nih.gov/pubmed/26348176>.
5. Vulvar Cancer Treatment- for health professionals (PDQ®). Bethesda, MD: 2015. Available at: <http://www.cancer.gov/types/vulvar/hp/vulvar-treatment-pdq#section/1>. Accessed August 3, 2015.
6. Stroup AM, Harlan LC, Trimble EL. Demographic, clinical, and treatment trends among women diagnosed with vulvar cancer in the United States. Gynecol Oncol 2008;108:577-583. Available at: <http://www.ncbi.nlm.nih.gov/pubmed/18155274>.
7. Figge DC. Rare Vulvar Malignancies. In: Greer BE, Berek JS, eds. Current Topics In Obstetrics And Gynecology: Gynecologic Oncology: Treatment Rationale And Techniques.: Elsevier; 1991:239-257.
8. Sideri M, Jones RW, Wilkinson EJ, et al. Squamous vulvar intraepithelial neoplasia: 2004 modified terminology, ISSVD Vulvar Oncology Subcommittee. J Reprod Med 2005;50:807-810. Available at: <https://www.ncbi.nlm.nih.gov/pubmed/16419625>.
9. Bornstein J, Bogliatto F, Haefner HK, et al. The 2015 International Society for the Study of Vulvovaginal Disease (ISSVD) Terminology of Vulvar Squamous Intraepithelial Lesions. Obstet Gynecol 2016;127:264-268. Available at: <http://www.ncbi.nlm.nih.gov/pubmed/26942352>.
10. Gillison ML, Chaturvedi AK, Lowy DR. HPV prophylactic vaccines and the potential prevention of noncervical cancers in both men and women. Cancer 2008;113:3036-3046. Available at: <https://www.ncbi.nlm.nih.gov/pubmed/18980286>.
11. Watson M, Saraiya M, Ahmed F, et al. Using population-based cancer registry data to assess the burden of human papillomavirus-associated cancers in the United States: overview of methods. Cancer 2008;113:2841-2854. Available at: <http://www.ncbi.nlm.nih.gov/pubmed/18980203>.
12. Gargano JW, Wilkinson EJ, Unger ER, et al. Prevalence of human papillomavirus types in invasive vulvar cancers and vulvar intraepithelial neoplasia 3 in the United States before vaccine introduction. J Low Genit Tract Dis 2012;16:471-479. Available at: <http://www.ncbi.nlm.nih.gov/pubmed/22652576>.
13. Eifel PJ, Berek JS, Markman MA. Cancer of the cervix, vagina, and vulva. In: DeVita VT, Lawrence TS, Rosenberg SA, eds. Principles and Practice of Oncology (ed 9). Philadelphia, PA: Lippincott Williams & Wilkins; 2011:1311-1344.
14. Hampl M, Deckers-Figiel S, Hampl JA, et al. New aspects of vulvar cancer: changes in localization and age of onset. Gynecol Oncol 2008;109:340-345. Available at: <http://www.ncbi.nlm.nih.gov/pubmed/18407339>.



NCCN Guidelines Version 1.2018

Vulvar Cancer (Squamous Cell Carcinoma)

15. Hacker NF. Revised FIGO staging for carcinoma of the vulva. Int J Gynaecol Obstet 2009;105:105-106. Available at: <http://www.ncbi.nlm.nih.gov/pubmed/19329116>.
16. Pecorelli S. Revised FIGO staging for carcinoma of the vulva, cervix, and endometrium. Int J Gynaecol Obstet 2009;105:103-104. Available at: <http://www.ncbi.nlm.nih.gov/pubmed/19367689>.
17. Amin MB, Edge SB, Greene FL, et al. AJCC Cancer Staging Manual, 8th edition. (ed 8). New York: Springer; 2016.
18. Li J, Cai Y, Ke G, et al. Validation of the new FIGO staging system (2009) for vulvar cancer in the Chinese population. Gynecol Oncol 2015;137:274-279. Available at: <http://www.ncbi.nlm.nih.gov/pubmed/25759305>.
19. Tabbaa ZM, Gonzalez J, Sznurkowski JJ, et al. Impact of the new FIGO 2009 staging classification for vulvar cancer on prognosis and stage distribution. Gynecol Oncol 2012;127:147-152. Available at: <http://www.ncbi.nlm.nih.gov/pubmed/22704951>.
20. Tan J, Chetty N, Kondalsamy-Chennakesavan S, et al. Validation of the FIGO 2009 staging system for carcinoma of the vulva. Int J Gynecol Cancer 2012;22:498-502. Available at: <http://www.ncbi.nlm.nih.gov/pubmed/22367324>.
21. Greer BE, Berek JS. Evolution of the Primary Treatment of Invasive Squamous Cell Carcinoma of the Vulva. In: Greer BE, Berek JS, eds. Current Topics In Obstetrics And Gynecology: Gynecologic Oncology: Treatment Rationale And Techniques: Elsevier; 1991:227-238.
22. Kataoka MY, Sala E, Baldwin P, et al. The accuracy of magnetic resonance imaging in staging of vulvar cancer: a retrospective multi-centre study. Gynecol Oncol 2010;117:82-87. Available at: <http://www.ncbi.nlm.nih.gov/pubmed/20092880>.
23. Cohn DE, Dehdashti F, Gibb RK, et al. Prospective evaluation of positron emission tomography for the detection of groin node metastases from vulvar cancer. Gynecol Oncol 2002;85:179-184. Available at: <http://www.ncbi.nlm.nih.gov/pubmed/11925141>.
24. Kamran MW, O'Toole F, Meghan K, et al. Whole-body [18F]fluoro-2-deoxyglucose positron emission tomography scan as combined PET-CT staging prior to planned radical vulvectomy and inguinofemoral lymphadenectomy for squamous vulvar cancer: a correlation with groin node metastasis. Eur J Gynaecol Oncol 2014;35:230-235. Available at: <http://www.ncbi.nlm.nih.gov/pubmed/24984533>.
25. Peiro V, Chiva L, Gonzalez A, et al. [Utility of the PET/CT in vulvar cancer management]. Rev Esp Med Nucl Imagen Mol 2014;33:87-92. Available at: <http://www.ncbi.nlm.nih.gov/pubmed/24095821>.
26. Robertson NL, Hricak H, Sonoda Y, et al. The impact of FDG-PET/CT in the management of patients with vulvar and vaginal cancer. Gynecol Oncol 2016;140:420-424. Available at: <https://www.ncbi.nlm.nih.gov/pubmed/26790773>.
27. Homesley HD, Bundy BN, Sedlis A, et al. Assessment of current International Federation of Gynecology and Obstetrics staging of vulvar carcinoma relative to prognostic factors for survival (a Gynecologic Oncology Group study). Am J Obstet Gynecol 1991;164:997-1003; discussion 1003-1004. Available at: <http://www.ncbi.nlm.nih.gov/pubmed/2014852>.
28. Burger MP, Hollema H, Emanuels AG, et al. The importance of the groin node status for the survival of T1 and T2 vulval carcinoma patients. Gynecol Oncol 1995;57:327-334. Available at: <http://www.ncbi.nlm.nih.gov/pubmed/7774836>.
29. Maggino T, Landoni F, Sartori E, et al. Patterns of recurrence in patients with squamous cell carcinoma of the vulva. A multicenter CTF Study. Cancer 2000;89:116-122. Available at: <http://www.ncbi.nlm.nih.gov/pubmed/10897008>.



NCCN Guidelines Version 1.2018

Vulvar Cancer (Squamous Cell Carcinoma)

30. van der Velden J, van Lindert AC, Lammes FB, et al. Extracapsular growth of lymph node metastases in squamous cell carcinoma of the vulva. The impact on recurrence and survival. *Cancer* 1995;75:2885-2890. Available at: <http://www.ncbi.nlm.nih.gov/pubmed/7773938>.

31. Luchini C, Nottegar A, Solmi M, et al. Prognostic implications of extranodal extension in node-positive squamous cell carcinoma of the vulva: A systematic review and meta-analysis. *Surg Oncol* 2016;25:60-65. Available at: <http://www.ncbi.nlm.nih.gov/pubmed/26394825>.

32. Origoni M, Sideri M, Garsia S, et al. Prognostic value of pathological patterns of lymph node positivity in squamous cell carcinoma of the vulva stage III and IVA FIGO. *Gynecol Oncol* 1992;45:313-316. Available at: <http://www.ncbi.nlm.nih.gov/pubmed/1612509>.

33. Raspagliesi F, Hanozet F, Ditto A, et al. Clinical and pathological prognostic factors in squamous cell carcinoma of the vulva. *Gynecol Oncol* 2006;102:333-337. Available at: <http://www.ncbi.nlm.nih.gov/pubmed/16466657>.

34. Heaps JM, Fu YS, Montz FJ, et al. Surgical-pathologic variables predictive of local recurrence in squamous cell carcinoma of the vulva. *Gynecol Oncol* 1990;38:309-314. Available at: <http://www.ncbi.nlm.nih.gov/pubmed/2227541>.

35. Homesley HD, Bundy BN, Sedlis A, et al. Prognostic factors for groin node metastasis in squamous cell carcinoma of the vulva (a Gynecologic Oncology Group study). *Gynecol Oncol* 1993;49:279-283. Available at: <http://www.ncbi.nlm.nih.gov/pubmed/8314530>.

36. Aragona AM, Cuneo NA, Soderini AH, Alcoba EB. An analysis of reported independent prognostic factors for survival in squamous cell carcinoma of the vulva: is tumor size significance being underrated? *Gynecol Oncol* 2014;132:643-648. Available at: <http://www.ncbi.nlm.nih.gov/pubmed/24418199>.

37. Rouzier R, Haddad B, Plantier F, et al. Local relapse in patients treated for squamous cell vulvar carcinoma: incidence and prognostic value. *Obstet Gynecol* 2002;100:1159-1167. Available at: <http://www.ncbi.nlm.nih.gov/pubmed/12468158>.

38. Figge DC, Tamimi HK, Greer BE. Lymphatic spread in carcinoma of the vulva. *Am J Obstet Gynecol* 1985;152:387-394. Available at: <http://www.ncbi.nlm.nih.gov/pubmed/4014331>.

39. Farias-Eisner R, Cirisano FD, Grouse D, et al. Conservative and individualized surgery for early squamous carcinoma of the vulva: the treatment of choice for stage I and II (T1-2N0-1M0) disease. *Gynecol Oncol* 1994;53:55-58. Available at: <http://www.ncbi.nlm.nih.gov/pubmed/8175023>.

40. Stehman FB, Look KY. Carcinoma of the vulva. *Obstet Gynecol* 2006;107:719-733. Available at: <http://www.ncbi.nlm.nih.gov/pubmed/16507947>.

41. Landrum LM, Lanneau GS, Skaggs VJ, et al. Gynecologic Oncology Group risk groups for vulvar carcinoma: improvement in survival in the modern era. *Gynecol Oncol* 2007;106:521-525. Available at: <http://www.ncbi.nlm.nih.gov/pubmed/17540438>.

42. Kim KW, Shinagare AB, Krajewski KM, et al. Update on imaging of vulvar squamous cell carcinoma. *AJR Am J Roentgenol* 2013;201:W147-157. Available at: <http://www.ncbi.nlm.nih.gov/pubmed/23789687>.

43. Slomovitz BM, Coleman RL, Oonk MH, et al. Update on sentinel lymph node biopsy for early-stage vulvar cancer. *Gynecol Oncol* 2015;138:472-477. Available at: <http://www.ncbi.nlm.nih.gov/pubmed/26022527>.

44. Magrina JF, Gonzalez-Bosquet J, Weaver AL, et al. Primary squamous cell cancer of the vulva: radical versus modified radical



NCCN Guidelines Version 1.2018

Vulvar Cancer (Squamous Cell Carcinoma)

vulvar surgery. Gynecol Oncol 1998;71:116-121. Available at:
<http://www.ncbi.nlm.nih.gov/pubmed/9784331>.

45. Ansink A, van der Velden J. Surgical interventions for early squamous cell carcinoma of the vulva. Cochrane Database Syst Rev 2000;CD002036. Available at:
<http://www.ncbi.nlm.nih.gov/pubmed/10796849>.

46. DeSimone CP, Van Ness JS, Cooper AL, et al. The treatment of lateral T1 and T2 squamous cell carcinomas of the vulva confined to the labium majus or minus. Gynecol Oncol 2007;104:390-395. Available at:
<http://www.ncbi.nlm.nih.gov/pubmed/17027067>.

47. De Hullu JA, Hollema H, Lolkema S, et al. Vulvar carcinoma. The price of less radical surgery. Cancer 2002;95:2331-2338. Available at:
<http://www.ncbi.nlm.nih.gov/pubmed/12436439>.

48. Viswanathan AN, Pinto AP, Schultz D, et al. Relationship of margin status and radiation dose to recurrence in post-operative vulvar carcinoma. Gynecol Oncol 2013;130:545-549. Available at:
<http://www.ncbi.nlm.nih.gov/pubmed/23747330>.

49. Chan JK, Sugiyama V, Pham H, et al. Margin distance and other clinico-pathologic prognostic factors in vulvar carcinoma: a multivariate analysis. Gynecol Oncol 2007;104:636-641. Available at:
<http://www.ncbi.nlm.nih.gov/pubmed/17095080>.

50. Faul CM, Mirmow D, Huang Q, et al. Adjuvant radiation for vulvar carcinoma: improved local control. Int J Radiat Oncol Biol Phys 1997;38:381-389. Available at:
<http://www.ncbi.nlm.nih.gov/pubmed/9226327>.

51. Woelber L, Eulenburg C, Grimm D, et al. The risk of contralateral non-sentinel metastasis in patients with primary vulvar cancer and unilaterally positive sentinel node. Ann Surg Oncol 2016. Available at:
<http://www.ncbi.nlm.nih.gov/pubmed/26856721>.

52. Coleman RL, Ali S, Levenback CF, et al. Is bilateral lymphadenectomy for midline squamous carcinoma of the vulva always necessary? An analysis from Gynecologic Oncology Group (GOG) 173. Gynecol Oncol 2013;128:155-159. Available at:
<http://www.ncbi.nlm.nih.gov/pubmed/23201592>.

53. DiSaia PJ, Creasman WT, Rich WM. An alternate approach to early cancer of the vulva. Am J Obstet Gynecol 1979;133:825-832. Available at:
<http://www.ncbi.nlm.nih.gov/pubmed/434024>.

54. Wills A, Obermair A. A review of complications associated with the surgical treatment of vulvar cancer. Gynecol Oncol 2013;131:467-479. Available at:
<http://www.ncbi.nlm.nih.gov/pubmed/23863358>.

55. Van der Zee AG, Oonk MH, De Hullu JA, et al. Sentinel node dissection is safe in the treatment of early-stage vulvar cancer. J Clin Oncol 2008;26:884-889. Available at:
<http://www.ncbi.nlm.nih.gov/pubmed/18281661>.

56. Oonk MH, van Hemel BM, Hollema H, et al. Size of sentinel-node metastasis and chances of non-sentinel-node involvement and survival in early stage vulvar cancer: results from GROINSS-V, a multicentre observational study. Lancet Oncol 2010;11:646-652. Available at:
<http://www.ncbi.nlm.nih.gov/pubmed/20537946>.

57. Oonk MH, van Os MA, de Bock GH, et al. A comparison of quality of life between vulvar cancer patients after sentinel lymph node procedure only and inguinofemoral lymphadenectomy. Gynecol Oncol 2009;113:301-305. Available at:
<http://www.ncbi.nlm.nih.gov/pubmed/19297013>.

58. Te Grootenhuys NC, van der Zee AG, van Doorn HC, et al. Sentinel nodes in vulvar cancer: Long-term follow-up of the GROningen International Study on Sentinel nodes in Vulvar cancer (GROINSS-V) I. Gynecol Oncol 2016;140:8-14. Available at:
<http://www.ncbi.nlm.nih.gov/pubmed/26428940>.

NCCN Guidelines Version 1.2018

Vulvar Cancer (Squamous Cell Carcinoma)

59. Levenback CF, Ali S, Coleman RL, et al. Lymphatic mapping and sentinel lymph node biopsy in women with squamous cell carcinoma of the vulva: a gynecologic oncology group study. *J Clin Oncol* 2012;30:3786-3791. Available at: <http://www.ncbi.nlm.nih.gov/pubmed/22753905>.

60. Covens A, Vella ET, Kennedy EB, et al. Sentinel lymph node biopsy in vulvar cancer: Systematic review, meta-analysis and guideline recommendations. *Gynecol Oncol* 2015;137:351-361. Available at: <http://www.ncbi.nlm.nih.gov/pubmed/25703673>.

61. Hacker NF, Berek JS, Lagasse LD, et al. Individualization of treatment for stage I squamous cell vulvar carcinoma. *Obstet Gynecol* 1984;63:155-162. Available at: <http://www.ncbi.nlm.nih.gov/pubmed/6694808>.

62. Burke TW, Levenback C, Coleman RL, et al. Surgical therapy of T1 and T2 vulvar carcinoma: further experience with radical wide excision and selective inguinal lymphadenectomy. *Gynecol Oncol* 1995;57:215-220. Available at: <http://www.ncbi.nlm.nih.gov/pubmed/7729737>.

63. Hacker NF, Van der Velden J. Conservative management of early vulvar cancer. *Cancer* 1993;71:1673-1677. Available at: <http://www.ncbi.nlm.nih.gov/pubmed/8431905>.

64. Morgan MA, Mikuta JJ. Surgical management of vulvar cancer. *Semin Surg Oncol* 1999;17:168-172. Available at: <http://www.ncbi.nlm.nih.gov/pubmed/10504664>.

65. van der Velden J, Fons G, Lawrie TA. Primary groin irradiation versus primary groin surgery for early vulvar cancer. *Cochrane Database Syst Rev* 2011;CD002224. Available at: <http://www.ncbi.nlm.nih.gov/pubmed/21563133>.

66. Stehman FB, Bundy BN, Thomas G, et al. Groin dissection versus groin radiation in carcinoma of the vulva: a Gynecologic Oncology

Group study. *Int J Radiat Oncol Biol Phys* 1992;24:389-396. Available at: <http://www.ncbi.nlm.nih.gov/pubmed/1526880>.

67. Hallak S, Ladi L, Sorbe B. Prophylactic inguinal-femoral irradiation as an alternative to primary lymphadenectomy in treatment of vulvar carcinoma. *Int J Oncol* 2007;31:1077-1085. Available at: <http://www.ncbi.nlm.nih.gov/pubmed/17912433>.

68. Petereit DG, Mehta MP, Buchler DA, Kinsella TJ. Inguinofemoral radiation of N0,N1 vulvar cancer may be equivalent to lymphadenectomy if proper radiation technique is used. *Int J Radiat Oncol Biol Phys* 1993;27:963-967. Available at: <http://www.ncbi.nlm.nih.gov/pubmed/8244830>.

69. Rouzier R, Haddad B, Atallah D, et al. Surgery for vulvar cancer. *Clin Obstet Gynecol* 2005;48:869-878. Available at: <http://www.ncbi.nlm.nih.gov/pubmed/16286833>.

70. Magrina JF, Gonzalez-Bosquet J, Weaver AL, et al. Squamous cell carcinoma of the vulva stage IA: long-term results. *Gynecol Oncol* 2000;76:24-27. Available at: <http://www.ncbi.nlm.nih.gov/pubmed/10620436>.

71. Yoder BJ, Rufforny I, Massoll NA, Wilkinson EJ. Stage IA vulvar squamous cell carcinoma: an analysis of tumor invasive characteristics and risk. *Am J Surg Pathol* 2008;32:765-772. Available at: <http://www.ncbi.nlm.nih.gov/pubmed/18379417>.

72. Wilkinson EJ. Superficial invasive carcinoma of the vulva. *Clin Obstet Gynecol* 1985;28:188-195. Available at: <http://www.ncbi.nlm.nih.gov/pubmed/3987129>.

73. Forner DM, Lampe B. Exenteration in the treatment of Stage III/IV vulvar cancer. *Gynecol Oncol* 2012;124:87-91. Available at: <http://www.ncbi.nlm.nih.gov/pubmed/21992967>.

NCCN Guidelines Version 1.2018

Vulvar Cancer (Squamous Cell Carcinoma)

74. Miller B, Morris M, Levenback C, et al. Pelvic exenteration for primary and recurrent vulvar cancer. *Gynecol Oncol* 1995;58:202-205. Available at: <http://www.ncbi.nlm.nih.gov/pubmed/7622106>.

75. Hoffman MS, Cavanagh D, Roberts WS, et al. Ultraradical surgery for advanced carcinoma of the vulva: an update. *Int J Gynecol Cancer* 1993;3:369-372. Available at: <http://www.ncbi.nlm.nih.gov/pubmed/11578371>.

76. Gadducci A, Cionini L, Romanini A, et al. Old and new perspectives in the management of high-risk, locally advanced or recurrent, and metastatic vulvar cancer. *Crit Rev Oncol Hematol* 2006;60:227-241. Available at: <http://www.ncbi.nlm.nih.gov/pubmed/16945551>.

77. Boronow RC. Combined therapy as an alternative to exenteration for locally advanced vulvo-vaginal cancer: rationale and results. *Cancer* 1982;49:1085-1091. Available at: <http://www.ncbi.nlm.nih.gov/pubmed/7059935>.

78. Fuh KC, Berek JS. Current management of vulvar cancer. *Hematol Oncol Clin North Am* 2012;26:45-62. Available at: <http://www.ncbi.nlm.nih.gov/pubmed/22244661>.

79. Leiserowitz GS, Russell AH, Kinney WK, et al. Prophylactic chemoradiation of inguinofemoral lymph nodes in patients with locally extensive vulvar cancer. *Gynecol Oncol* 1997;66:509-514. Available at: <http://www.ncbi.nlm.nih.gov/pubmed/9299268>.

80. Russell AH, Mesic JB, Scudder SA, et al. Synchronous radiation and cytotoxic chemotherapy for locally advanced or recurrent squamous cancer of the vulva. *Gynecol Oncol* 1992;47:14-20. Available at: <http://www.ncbi.nlm.nih.gov/pubmed/1427394>.

81. Thomas G, Dembo A, DePetrillo A, et al. Concurrent radiation and chemotherapy in vulvar carcinoma. *Gynecol Oncol* 1989;34:263-267. Available at: <http://www.ncbi.nlm.nih.gov/pubmed/2504651>.

82. Eifel PJ, Morris M, Burke TW, et al. Prolonged continuous infusion cisplatin and 5-fluorouracil with radiation for locally advanced carcinoma of the vulva. *Gynecol Oncol* 1995;59:51-56. Available at: <http://www.ncbi.nlm.nih.gov/pubmed/7557615>.

83. Lupi G, Raspagliesi F, Zucali R, et al. Combined preoperative chemoradiotherapy followed by radical surgery in locally advanced vulvar carcinoma. A pilot study. *Cancer* 1996;77:1472-1478. Available at: <http://www.ncbi.nlm.nih.gov/pubmed/8608531>.

84. Moore DH, Thomas GM, Montana GS, et al. Preoperative chemoradiation for advanced vulvar cancer: a phase II study of the Gynecologic Oncology Group. *Int J Radiat Oncol Biol Phys* 1998;42:79-85. Available at: <http://www.ncbi.nlm.nih.gov/pubmed/9747823>.

85. Geisler JP, Manahan KJ, Buller RE. Neoadjuvant chemotherapy in vulvar cancer: avoiding primary exenteration. *Gynecol Oncol* 2006;100:53-57. Available at: <http://www.ncbi.nlm.nih.gov/pubmed/16257042>.

86. Landoni F, Maneo A, Zanetta G, et al. Concurrent preoperative chemotherapy with 5-fluorouracil and mitomycin C and radiotherapy (FUMIR) followed by limited surgery in locally advanced and recurrent vulvar carcinoma. *Gynecol Oncol* 1996;61:321-327. Available at: <http://www.ncbi.nlm.nih.gov/pubmed/8641609>.

87. Berek JS, Heaps JM, Fu YS, et al. Concurrent cisplatin and 5-fluorouracil chemotherapy and radiation therapy for advanced-stage squamous carcinoma of the vulva. *Gynecol Oncol* 1991;42:197-201. Available at: <http://www.ncbi.nlm.nih.gov/pubmed/1955180>.

88. Koh WJ, Wallace HJ, 3rd, Greer BE, et al. Combined radiotherapy and chemotherapy in the management of local-regionally advanced vulvar cancer. *Int J Radiat Oncol Biol Phys* 1993;26:809-816. Available at: <http://www.ncbi.nlm.nih.gov/pubmed/8344850>.

NCCN Guidelines Version 1.2018

Vulvar Cancer (Squamous Cell Carcinoma)

89. Cunningham MJ, Goyer RP, Gibbons SK, et al. Primary radiation, cisplatin, and 5-fluorouracil for advanced squamous carcinoma of the vulva. *Gynecol Oncol* 1997;66:258-261. Available at: <http://www.ncbi.nlm.nih.gov/pubmed/9264573>.

90. Gerszten K, Selvaraj RN, Kelley J, Faul C. Preoperative chemoradiation for locally advanced carcinoma of the vulva. *Gynecol Oncol* 2005;99:640-644. Available at: <http://www.ncbi.nlm.nih.gov/pubmed/16169579>.

91. Tans L, Ansink AC, van Rooij PH, et al. The role of chemo-radiotherapy in the management of locally advanced carcinoma of the vulva: single institutional experience and review of literature. *Am J Clin Oncol* 2011;34:22-26. Available at: <http://www.ncbi.nlm.nih.gov/pubmed/20087157>.

92. Han SC, Kim DH, Higgins SA, et al. Chemoradiation as primary or adjuvant treatment for locally advanced carcinoma of the vulva. *Int J Radiat Oncol Biol Phys* 2000;47:1235-1244. Available at: <http://www.ncbi.nlm.nih.gov/pubmed/10889377>.

93. Montana GS, Thomas GM, Moore DH, et al. Preoperative chemoradiation for carcinoma of the vulva with N2/N3 nodes: a gynecologic oncology group study. *Int J Radiat Oncol Biol Phys* 2000;48:1007-1013. Available at: <http://www.ncbi.nlm.nih.gov/pubmed/11072157>.

94. Moore DH, Ali S, Koh WJ, et al. A phase II trial of radiation therapy and weekly cisplatin chemotherapy for the treatment of locally-advanced squamous cell carcinoma of the vulva: a gynecologic oncology group study. *Gynecol Oncol* 2012;124:529-533. Available at: <http://www.ncbi.nlm.nih.gov/pubmed/22079361>.

95. Shylasree TS, Bryant A, Howells RE. Chemoradiation for advanced primary vulval cancer. *Cochrane Database Syst Rev* 2011:CD003752. Available at: <http://www.ncbi.nlm.nih.gov/pubmed/21491387>.

96. van Doorn HC, Ansink A, Verhaar-Langereis M, Stalpers L. Neoadjuvant chemoradiation for advanced primary vulvar cancer. *Cochrane Database Syst Rev* 2006:CD003752. Available at: <http://www.ncbi.nlm.nih.gov/pubmed/16856018>.

97. Reade CJ, Eiriksson LR, Mackay H. Systemic therapy in squamous cell carcinoma of the vulva: current status and future directions. *Gynecol Oncol* 2014;132:780-789. Available at: <http://www.ncbi.nlm.nih.gov/pubmed/24296343>.

98. Chin JY, Hong TS, Ryan DP. Mitomycin in anal cancer: still the standard of care. *J Clin Oncol* 2012;30:4297-4301. Available at: <http://www.ncbi.nlm.nih.gov/pubmed/23150704>.

99. Han SN, Vergote I, Amant F. Weekly paclitaxel/carboplatin in the treatment of locally advanced, recurrent, or metastatic vulvar cancer. *Int J Gynecol Cancer* 2012;22:865-868. Available at: <http://www.ncbi.nlm.nih.gov/pubmed/22552830>.

100. Witteveen PO, van der Velden J, Vergote I, et al. Phase II study on paclitaxel in patients with recurrent, metastatic or locally advanced vulvar cancer not amenable to surgery or radiotherapy: a study of the EORTC-GCG (European Organisation for Research and Treatment of Cancer--Gynaecological Cancer Group). *Ann Oncol* 2009;20:1511-1516. Available at: <http://www.ncbi.nlm.nih.gov/pubmed/19487487>.

101. Horowitz NS, Olawaiye AB, Borger DR, et al. Phase II trial of erlotinib in women with squamous cell carcinoma of the vulva. *Gynecol Oncol* 2012;127:141-146. Available at: <http://www.ncbi.nlm.nih.gov/pubmed/22750258>.

102. Jolly S, Soni P, Gaffney DK, et al. ACR Appropriateness Criteria(R) Adjuvant Therapy in Vulvar Cancer. *Oncology (Williston Park)* 2015;29:867-872, 874-865. Available at: <http://www.ncbi.nlm.nih.gov/pubmed/26568534>.

103. Homesley HD, Bundy BN, Sedlis A, Adcock L. Radiation therapy versus pelvic node resection for carcinoma of the vulva with positive groin nodes. *Obstet Gynecol* 1986;68:733-740. Available at: <http://www.ncbi.nlm.nih.gov/pubmed/3785783>.

104. Kunos C, Simpkins F, Gibbons H, et al. Radiation therapy compared with pelvic node resection for node-positive vulvar cancer: a randomized controlled trial. *Obstet Gynecol* 2009;114:537-546. Available at: <http://www.ncbi.nlm.nih.gov/pubmed/19701032>.

105. Fons G, Groenen SM, Oonk MH, et al. Adjuvant radiotherapy in patients with vulvar cancer and one intra capsular lymph node metastasis is not beneficial. *Gynecol Oncol* 2009;114:343-345. Available at: <http://www.ncbi.nlm.nih.gov/pubmed/19481242>.

106. Mahner S, Jueckstock J, Hilpert F, et al. Adjuvant therapy in lymph node-positive vulvar cancer: the AGO-CaRE-1 study. *J Natl Cancer Inst* 2015;107. Available at: <http://www.ncbi.nlm.nih.gov/pubmed/25618900>.

107. Parthasarathy A, Cheung MK, Osann K, et al. The benefit of adjuvant radiation therapy in single-node-positive squamous cell vulvar carcinoma. *Gynecol Oncol* 2006;103:1095-1099. Available at: <http://www.ncbi.nlm.nih.gov/pubmed/16889821>.

108. Woelber L, Eulenburg C, Choschzick M, et al. Prognostic role of lymph node metastases in vulvar cancer and implications for adjuvant treatment. *Int J Gynecol Cancer* 2012;22:503-508. Available at: <http://www.ncbi.nlm.nih.gov/pubmed/22266935>.

109. Dusenbery KE, Carlson JW, LaPorte RM, et al. Radical vulvectomy with postoperative irradiation for vulvar cancer: therapeutic implications of a central block. *Int J Radiat Oncol Biol Phys* 1994;29:989-998. Available at: <http://www.ncbi.nlm.nih.gov/pubmed/8083101>.

110. Gill BS, Bernard ME, Lin JF, et al. Impact of adjuvant chemotherapy with radiation for node-positive vulvar cancer: A National

Cancer Data Base (NCDB) analysis. *Gynecol Oncol* 2015;137:365-372. Available at: <http://www.ncbi.nlm.nih.gov/pubmed/25868965>.

111. Swanick CW, Smith GL, Huo J, et al. (P021) Delivery and outcomes of adjuvant radiation therapy in older women with node-positive vulvar cancer. *Oncology (Williston Park)* 2016;30. Available at: <http://www.ncbi.nlm.nih.gov/pubmed/27083660>.

112. Ignatov T, Eggemann H, Burger E, et al. Adjuvant radiotherapy for vulvar cancer with close or positive surgical margins. *J Cancer Res Clin Oncol* 2016;142:489-495. Available at: <http://www.ncbi.nlm.nih.gov/pubmed/26498775>.

113. van Beekhuizen HJ, Auzin M, van den Einden LC, et al. Lymph node count at inguinofemoral lymphadenectomy and groin recurrences in vulvar cancer. *Int J Gynecol Cancer* 2014;24:773-778. Available at: <http://www.ncbi.nlm.nih.gov/pubmed/24662136>.

114. Bell JG, Lea JS, Reid GC. Complete groin lymphadenectomy with preservation of the fascia lata in the treatment of vulvar carcinoma. *Gynecol Oncol* 2000;77:314-318. Available at: <http://www.ncbi.nlm.nih.gov/pubmed/10785485>.

115. Stehman FB, Bundy BN, Dvoretzky PM, Creasman WT. Early stage I carcinoma of the vulva treated with ipsilateral superficial inguinal lymphadenectomy and modified radical hemivulvectomy: a prospective study of the Gynecologic Oncology Group. *Obstet Gynecol* 1992;79:490-497. Available at: <http://www.ncbi.nlm.nih.gov/pubmed/1553164>.

116. Kirby TO, Rocconi RP, Numnum TM, et al. Outcomes of Stage I/II vulvar cancer patients after negative superficial inguinal lymphadenectomy. *Gynecol Oncol* 2005;98:309-312. Available at: <http://www.ncbi.nlm.nih.gov/pubmed/15975642>.

117. Gonzalez Bosquet J, Magrina JF, Gaffey TA, et al. Long-term survival and disease recurrence in patients with primary squamous cell



National
Comprehensive
Cancer
Network®

NCCN Guidelines Version 1.2018

Vulvar Cancer (Squamous Cell Carcinoma)

[NCCN Guidelines Index](#)
[Table of Contents](#)
[Discussion](#)

carcinoma of the vulva. *Gynecol Oncol* 2005;97:828-833. Available at: <http://www.ncbi.nlm.nih.gov/pubmed/15896831>.

118. Elit L, Reade CJ. Recommendations for Follow-up Care for Gynecologic Cancer Survivors. *Obstet Gynecol* 2015;126:1207-1214. Available at: <http://www.ncbi.nlm.nih.gov/pubmed/26551194>.

119. Salani R, Backes FJ, Fung MF, et al. Posttreatment surveillance and diagnosis of recurrence in women with gynecologic malignancies: Society of Gynecologic Oncologists recommendations. *Am J Obstet Gynecol* 2011;204:466-478. Available at: <http://www.ncbi.nlm.nih.gov/pubmed/21752752>.

120. Hazewinkel MH, Laan ET, Sprangers MA, et al. Long-term sexual function in survivors of vulvar cancer: a cross-sectional study. *Gynecol Oncol* 2012;126:87-92. Available at: <http://www.ncbi.nlm.nih.gov/pubmed/22516660>.

121. Westin SN, Sun CC, Tung CS, et al. Survivors of gynecologic malignancies: impact of treatment on health and well-being. *J Cancer Surviv* 2016;10:261-270. Available at: <http://www.ncbi.nlm.nih.gov/pubmed/26245979>.

122. Mahner S, Prieske K, Grimm D, et al. Systemic treatment of vulvar cancer. *Expert Rev Anticancer Ther* 2015;15:629-637. Available at: <http://www.ncbi.nlm.nih.gov/pubmed/25997120>.

123. Salom EM, Penalver M. Recurrent vulvar cancer. *Curr Treat Options Oncol* 2002;3:143-153. Available at: <http://www.ncbi.nlm.nih.gov/pubmed/12057077>.

124. Piura B, Masotina A, Murdoch J, et al. Recurrent squamous cell carcinoma of the vulva: a study of 73 cases. *Gynecol Oncol* 1993;48:189-195. Available at: <http://www.ncbi.nlm.nih.gov/pubmed/8428690>.

125. Raffetto N, Tombolini V, Santarelli M, et al. Radiotherapy alone and chemoradiation in recurrent squamous cell carcinoma of the vulva. *Anticancer Res* 2003;23:3105-3108. Available at: <http://www.ncbi.nlm.nih.gov/pubmed/12926170>.

126. Podratz KC, Symmonds RE, Taylor WF, Williams TJ. Carcinoma of the vulva: analysis of treatment and survival. *Obstet Gynecol* 1983;61:63-74. Available at: <http://www.ncbi.nlm.nih.gov/pubmed/6823350>.

127. Chiantera V, Rossi M, De Iaco P, et al. Morbidity after pelvic exenteration for gynecological malignancies: a retrospective multicentric study of 230 patients. *Int J Gynecol Cancer* 2014;24:156-164. Available at: <http://www.ncbi.nlm.nih.gov/pubmed/24362721>.

128. Stehman FB, Bundy BN, Ball H, Clarke-Pearson DL. Sites of failure and times to failure in carcinoma of the vulva treated conservatively: a Gynecologic Oncology Group study. *Am J Obstet Gynecol* 1996;174:1128-1132; discussion 1132-1123. Available at: <http://www.ncbi.nlm.nih.gov/pubmed/8623839>.

129. Hopkins MP, Reid GC, Morley GW. The surgical management of recurrent squamous cell carcinoma of the vulva. *Obstet Gynecol* 1990;75:1001-1005. Available at: <https://www.ncbi.nlm.nih.gov/pubmed/2342725>.

130. Bellati F, Angioli R, Mancini N, et al. Single agent cisplatin chemotherapy in surgically resected vulvar cancer patients with multiple inguinal lymph node metastases. *Gynecol Oncol* 2005;96:227-231. Available at: <http://www.ncbi.nlm.nih.gov/pubmed/15589606>.

131. Cormio G, Loizzi V, Gissi F, et al. Cisplatin and vinorelbine chemotherapy in recurrent vulvar carcinoma. *Oncology* 2009;77:281-284. Available at: <http://www.ncbi.nlm.nih.gov/pubmed/19923866>.

132. Kitagawa R, Katsumata N, Shibata T, et al. Paclitaxel plus carboplatin versus paclitaxel plus cisplatin in metastatic or recurrent



National
Comprehensive
Cancer
Network®

NCCN Guidelines Version 1.2018 Vulvar Cancer (Squamous Cell Carcinoma)

[NCCN Guidelines Index](#)
[Table of Contents](#)
[Discussion](#)

cervical cancer: the open-label randomized phase III trial JCOG0505. J
Clin Oncol 2015;33:2129-2135. Available at:
<http://www.ncbi.nlm.nih.gov/pubmed/25732161>.

A large, light gray circular watermark is centered on the page. It contains the text "Discussion update in progress" in a bold, sans-serif font, arranged in three lines.

Discussion
update in
progress